

MORPHOLOGY AND MORPHOMETRIC STUDY ON ANATOMICAL VARIATIONS OF JUGULAR FORAMEN IN ADULT HUMAN SKULLS

T.L.Anbumani ¹, M.Raja ^{*2}, A.Thamarai Selvi ³.

¹ Professor and Head of the Department, Department of Anatomy. KarpagaVinayaga Institute of Medical Sciences, Madurantakam Taluk, Kanchipuram District, Tamil Nadu, India.

^{*2} Post graduate, KarpagaVinayaga Institute of Medical Sciences, Madurantakam Taluk, Kanchipuram District, Tamil Nadu, India.

³ Assistant Professor, KarpagaVinayaga Institute of Medical Sciences, Madurantakam Taluk, Kanchipuram District, Tamil Nadu, India.

ABSTRACT

Background: Jugular foramen, a large irregular foramen at the base of the skull, lies at the posterior end of petro occipital suture between jugular process of occipital bone and jugular fossa of petrous part of temporal bone; above and lateral to foramen magnum. Many important structures pass through this foramen. Among these are Inferior Petrosal Sinus, presence of three cranial nerves 9, 10, and 11 and Internal Jugular vein. The increasing use of modern diagnostic procedures and new surgical approaches has created a need for much more detailed anatomical studies and explanations.

Materials and Methods: The study was conducted in Osteology lab of Anatomy Department, KarpagaVinayaga Institute of Medical Sciences, Chinnakolambakkam, Madurantakam taluk, Tamilnadu (India). 66 jugular foramina of 33 Adult human skulls have been examined for study.

Results and Conclusion: The morphometric and morphological analysis of jugular foramen were done in 33 skulls, and the results obtained are mentioned below. The Mean average width of foramen is 15.26mm and the Range is between 10mm and 21mm. The Mean average length of foramen is 10mm and the Range is between 6mm and 14mm. Regarding, the size of the foramina; the Right side is larger than the Left side. Incomplete Intrajugular process is the commonest observation observed (in 64 foramina). Regarding, Intra Jugular Process contribution for foramen, it is mainly from Temporal bone. Separate foramen for IPS was found only in one foramen out of 66 foramina observed. The height of dome of jugular fossa is more on the Right than on the Left side (in 60.6% of skulls). The range of Height of the Dome is 6.41mm to 18.46mm and the Mean average is 12.11mm.

KEY WORDS: Jugular foramen, Jugular fossa, Skull, Sigmoid Sinus, Inferior Petrosal Sinus. Compartment, Internal Jugular Vein.

Address for Correspondence: Dr. M.Raja, MD Anatomy Post graduate, KarpagaVinayaga Institute of Medical Sciences, Madurantakam Taluk, Kanchipuram District, Tamil Nadu, India.

E-Mail: Jeyamraja2015@gmail.com

Access this Article online	Journal Information
Quick Response code  DOI: 10.16965/ijar.2019.130	International Journal of Anatomy and Research ICV for 2016 90.30 ISSN (E) 2321-4287 ISSN (P) 2321-8967 https://www.ijmhr.org/ijar.htm DOI-Prefix: https://dx.doi.org/10.16965/ijar 
	Article Information
	Received: 30 Jan 2019 Peer Review: 30 Jan 2019 Revised: None
	Accepted: 07 Mar 2019 Published (O): 05 Apr 2019 Published (P): 05 Apr 2019

INTRODUCTION

Jugular foramen, a large irregular bilateral foramen at the base of the skull, lies at the posterior end of petro occipital suture between

jugular process of occipital bone and jugular fossa of petrous part of temporal bone; above and lateral to foramen magnum [1]. Jugular Foramen is a large, irregular opening, the long

axis being directed forwards and medially. The foramen is bounded in front by the jugular fossa of petrous temporal bone and behind by jugular process of occipital bone. The anterior margin of jugular process is free and is called jugular notch which forms the posterior boundary of jugular foramen. This important foramen is subdivided into three compartments by two bony spicules known as intrajugular processes [2]:

Anterior vascular compartment: transmits Inferior Petrosal sinus-(a first tributary of Internal Jugular vein) drains into the superior bulb of Internal Jugular vein.

Middle compartment for Nerves: from before backwards—9th, 10th and 11th cranial nerves, meningeal branch of Ascending pharyngeal artery^{3,4}, occasionally emissary vein.

Posterior vascular compartment: Sigmoid sinus—continuous as internal jugular vein.

Many intracranial and extra cranial lesions of posterior cranial fossa may affect the above mentioned structures in the jugular foramen. Many pathological tumours like schwannomas, meningiomas, paragangliomas and glomus jugulare tumour and inflammatory lesions of inner ear will also disturb structures in the jugular foramen [5]. Nowadays, as many neurosurgeons have started approaching this region, so arises a need of familiarity in this region.

Aims and Objectives:

This study is aimed, to study and provide the knowledge about variations in the morphology and morphometric of an important foramen in the skull, the jugular foramen.

The aim is to measure and study the jugular foramen with the following Osteometric Parameters:

I. Size of Foramina:

1. Antero Posterior Measurement (Width).
2. Medial to Lateral Measurement (Length).

II. Intra Jugular Processes (Septation):

- a) Intra Jugular Process—Present or Absent.
- b) Intra Jugular Process—Complete or Incomplete.
- c) Number of Intra Jugular Process Present in the foramen.

d) Intra Jugular Process contribution is from which bone (Occipital or Temporal).

III. Jugular Fossa: Height of the Dome of jugular fossa.

MATERIALS AND METHODS

The study was conducted in Osteology lab of Anatomy Department Karpaga Vinayaga Institute of Medical Sciences, Chinnakolambakkam, Madurantakam taluk, Tamilnadu. 66 jugular foramina of 33 Adult human skulls have been examined for study.

Inclusion Criteria: Adult Healthy Human skulls were taken for study.

Exclusion Criteria: Deformed and Eroded skulls.

Study Type: This is a Cross-sectional descriptive type.

Several dimensions like Length, Width of jugular foramina were measured with **sliding Digital Vernier Callipers, Thread and Scale**. Jugular foramina were studied for a review of its morphology, morphometry and were compared with previous studies. Intra Jugular Process was also observed.

OBSERVATIONS AND RESULTS

The morphometric and morphological analysis of jugular foramen were done in 33 skulls, and the results of observations are as follows:

Size of Foramina:

Antero Posterior Measurement (Width) of jugular foramina: The Mean average width i.e. Antero Posterior measurement of foramen is 15.26mm and the Range is between 10mm and 21mm. Right side width is more than Left side in 60.60% of skulls side (Table. 1).

Table 1: Antero Posterior Measurement (Width) of jugular foramina.

Width of Foramina	Right > Left in		Right < Left in		Right = Left in	
	Nos	Percentage	Nos	Percentage	Nos	Percentage
	20 skulls	60.60%	9 skulls	27.27%	4 skulls	12.12%

Medio Lateral Measurement (Length) of jugular foramina: The Mean average length of foramen is 10mm and the Range is between 6mm and 14mm. Similar to the width of the foramina, the length on the Right side is more than on the Left side, present in 72.72% of observed skulls (Table. 2).

Table 2: MedioLateral Measurement (Length) of jugular foramina.

Length of Foramina	Right > Left in		Right<Left in		Right=Left in	
	Nos	Percentage	Nos	Percentage	Nos	Percentage
	24 skulls	72.72%	6 skulls	18.18%	3 skulls	9.09%

On observation with the mean average width and the mean average length for the size of the foramina, it is inferred that the Right side is larger than the Left side in the majority of skulls observed. Right side is larger, both in its width and length; found in almost 60 to 72% of skulls studied. This is further evidenced on observation, by the presence of large sigmoid sinus impression found on Right side in those skulls. (Fig.:1&2).

Fig. 1: Shows the Size of the Jugular foramen is larger on Right side than on Left side (Arrow) and Height of the Dome of jugular fossa is larger on Right side.

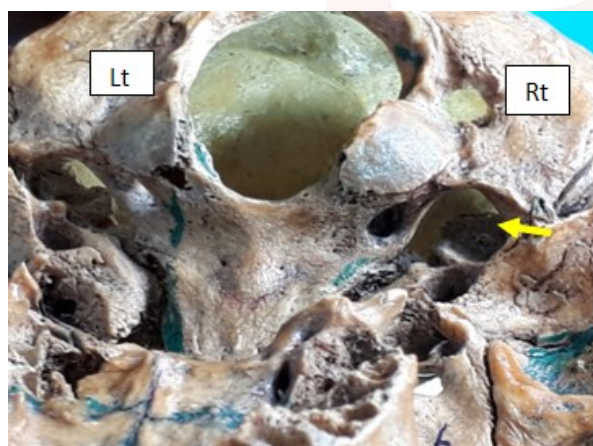
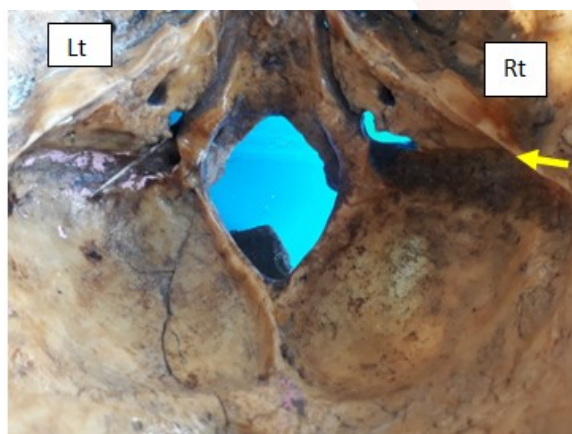


Fig. 2: Arrow shows the Evidence of large sigmoidal impression on Right side (correlating with the larger size of foramen on Right side).



Intra Jugular Processes(Septation):

Intra Jugular Process- Present or Absent: The intra jugular processes are present in all the 66 foramina observed.

Intra Jugular Process—Complete or Incomplete: The intra jugular processes is incomplete

in 65 foramina, whereas it is complete in one foramen i.e.on the left side of skull to make it into a compartment (Table.3). The complete septation found in this foramen, has created a separate foramen for Inferior Petrosal Sinus (Figure 4).

Table 3: Complete or Incomplete Intra Jugular Process.

Intra jugular process	Complete	Incomplete	
Side of the Skull	On Left Side only	Right	Left
Nos	1	33	32

Number of Intra Jugular Process Present in the foramen:

The results show that one number, two numbers and three numbers of intra jugular processes were present in 57.57%, 40.90% and 1.51% of skulls respectively. The analysis also shows that one number (30.30%) and two numbers (36.36%) of intra jugular processes were mostly present on the Right side (Table.4).

Table 4: Number of Intra Jugular Processes present in the foramen.

Number of Intra Jugular Processes	One Number present in		Two Numbers Present in		Three Numbers present in	
	Nos	%	Nos	%	Nos	%
	38 foramina	57.57%	27 foramina	40.90%	1 foramen	1.51%

Intra Jugular Process contribution is from which bone (Occipital or Temporal): Intra Jugular Process Contribution is mostly from Temporal bone, found almost in 46 foramina. Intra Jugular Process contribution from both bones is seen in 10 foramina and is shown in Figure 3. As the intrajugular process (septation) is complete in one foramen, the contribution from which bone on that side (Left side) could not be ascertained.

Table 5: Intra Jugular Processes contribution from which bone.

Intra Jugular Processes contribution from	Temporal bone	Occipital bone	Both bones
Number of foramina	46	10	9
Percentage(%)	70.76%	15.38%	13.84%

Height of the Dome of jugular fossa: The height of the dome of jugular fossa was also observed on both sides. The Range of Height of the Dome is 6.41mm to 18.46mm and the Mean average is 12.11mm. The height of dome of jugular fossa is more on the Right than on the Left side in

majority of skulls observed, accounting to 60.60% of skulls (Figure 1). Right dome height is less than left in 39.39% of skulls.

Fig. 3: Intra Jugular Process contribution from both temporal and occipital bones on Right side is shown with arrows.


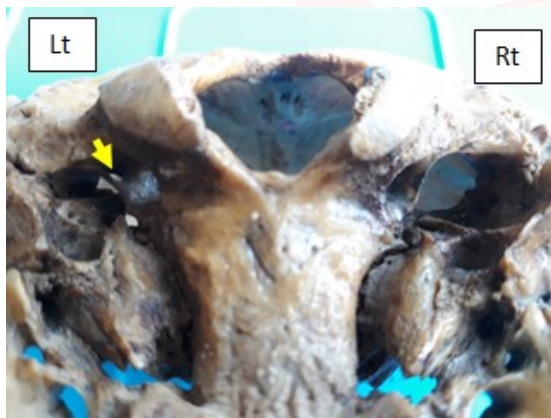


Fig. 4: Arrow Show separate foramen for Inferior Petrosal Sinus along with the Jugular foramen on Left Side.



DISCUSSION

The anomalies of jugular bulb are associated with the jugular foramen. The Glomus tumors, Glomus jugulare tumour grow in and around the foramen are mostly in direct contact with structures that cross jugular foramen. Tumours such as schwannomas, metastatic lesions and infiltrating inflammatory processes can also cause compression of important cranial nerves involved with hearing. Hence, a complete otological and neurological examination has to be done before surgically accessing any lesion in this area.

Size of Foramina: Sturrock(1988) [6] stated that the size and shape of the jugular foramen is related to the size of the internal jugular vein and the presence or absence of a prominent superior bulb.

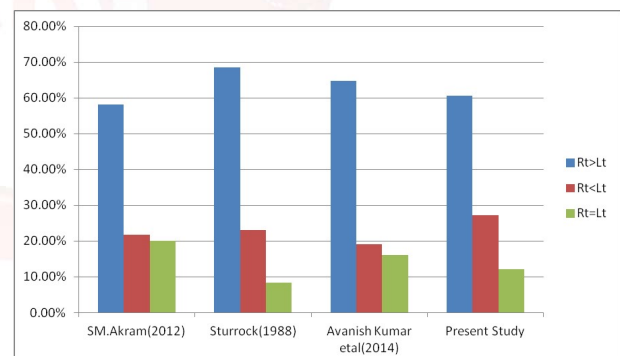
Sturrock has observed that 68.6% were larger on the right side and 23.1% on left side and 8.3%

of equal size. The present study had observed 60.6% larger jugular foramen on right side and 27.2% larger on left side, whereas the right and left jugular foramen were found to be equal size in 12.1%. The size of the foramina on Right side is larger than the Left side. This finding coincides with all the Authors mentioned below in the Bar Chart 1.

Width: The Study by SM.Akram (2012) [7] the Width is between 6mm and 10mm and in Avanishkumaretal⁸(2014) Study width is between 8.5 mm and 13.5 mm. In the present study the Mean average width of foramen is 15.26mm and the Range is between 10mm and 21mm.

Length: Avaniskumar et al [8] shows the mean length is 13.6 mm. In ShifanKhanday et al [5] the mean length was 14.6 mm on right side and 13.9 mm on left side. In Present study the Mean average length of foramen is 10mm and the Range is between 6mm and 14mm.

Bar Chart 1: Size of Foramina—a comparative analysis with other Authors.



Intra Jugular Processes(Septation):

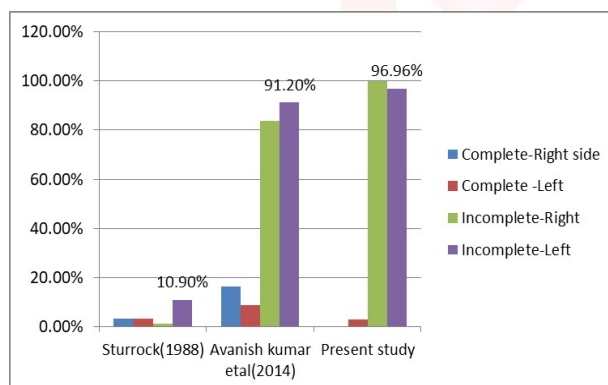
Intra Jugular Process -Present or Absent: The intra jugular processes are present in all the 66 foramina observed.

Intra Jugular Process—Complete or Incomplete: Sturrock [6] observed that the complete septation of jugular foramen was present on right side in 3.2% and left side in 3.2%. Partial or incomplete septation on right side in 1.3% and on Left side in 10.9%. In Present Study the intra jugular processes is incomplete in 65 foramina, whereas it is complete in one foramen i.e. on the left side of the skull to make it into a compartment (Ref: Table.3). The complete septation found in this foramen, has created a separate foramen for Inferior Petrosal Sinus. Present study observed that intra jugular

process is complete on only Left side in 3.33%. The values of complete septation is correlating with Sturrock⁶ study. Partial or incomplete intrajugular process (septation) seen on right side and on left side in 100% and in 96.9% of skulls respectively. This value to some extent it comes close to the values found in Avanishkumaretal [8]. A comparative analysis of Intra jugular Process-complete or Incomplete is depicted in Bar Chart.2.

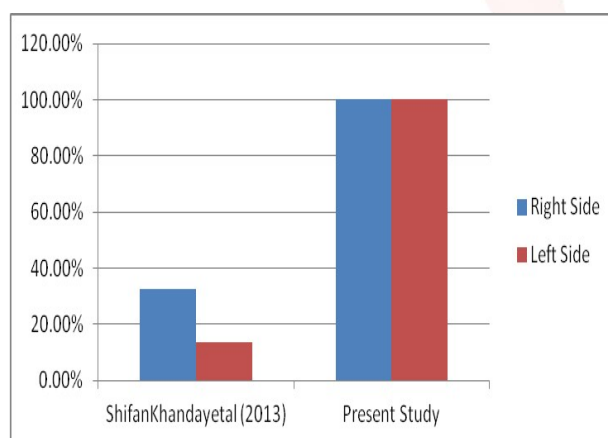
Separate foramen for IPS was found only in one foramen outof 66 foramina observed i.e. accounting to 1.5%; whereas in the study by Shifan Khanday et al (2013) [5] on 324 skull foramina, it was present in 18.4%.

Bar Chart 2: Intra Jugular Process —Complete and Partial – a comparative study.



Number of Intra Jugular Process Present in the foramen: Small bony spurs projecting in to the jugular foramen were seen in all foramina observed. Their numbers are tabulated in Table.4.

Bar Chart 3: Comparison of presence of Intra Jugular Processes in both sides.

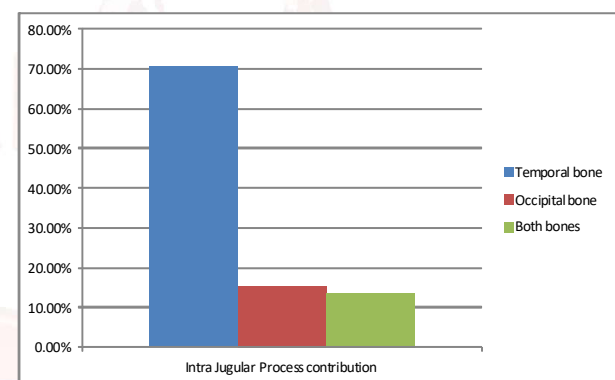


The results show that one number, two numbers and three numbers of intra jugular processes were present in 57.57%, 40.90% and 1.51% of skulls respectively. The analysis also shows that

one number (30.30%) and two numbers (36.36%) of intra jugular processes were mostly present on the Right side. Spicules present in 46.29 % (32.70% on Right side and 13.58% on Left side) of foramina observed in ShifanKhanday et al (2013) [5]. Presence of spicules is 50% more than the ShifanKhandayetal⁵. This is shown in Bar Chart 3.

Intra Jugular Process contribution from which bone (Occipital or Temporal): Intra Jugular Process Contribution is mostly from Temporal bone, found almost in 70.76 % foramina. Intra Jugular Process contribution from both bones is seen in 15.38 % foramina and is shown in Figure.3. This is depicted in Bar Chart.4. As the intrajugular process (septation) is complete in one foramen, the contribution from which bone on that side (Left side) could not be ascertained.

Bar Chart 4: Percentage of Bone Contribution of Intra Jugular Process.



Height of the Dome of jugular fossa: The height of the dome of jugular fossa was also observed on both sides. The Range of Height of the Dome is 6.41mm to 18.46mm and the Mean average is 12.11mm. The height of dome of jugular fossa is more on the Right than on the Left side in majority of skulls observed, accounting to 60.60% of skulls (Figure 1). Right dome height is less than left in 39.39% of skulls.

In Shifan Khandayn et al [5] the mean height on right side is 10.1 mm and 9mm on left side. In the Present Study the Range of Height of the Dome is 6.41mm to 18.46 mm and the Mean average is 12.11mm.

CONCLUSION

The variations reported in present study and in other studies may be due to various factors such as race, constitution and genetics and geographical factors. The increasing use of modern

diagnostic procedures and new surgical approaches has created a need for much more detailed anatomical studies and explanations. Therefore, a thorough knowledge of complex anatomy of the jugular foramen is of utmost importance to neurosurgeons and otolaryngologists. Hence, this study will throw a light on the mandatory importance of thorough otological and neurological examination has to be done before surgically accessing this area.

ABBREVIATION

mm- Millimeter

Rts - Right

Lt- Left

IPS - Inferior Petrosal Sinus.

% - Percent.

Conflicts of Interests: None

REFERENCES

- [1]. Gray's Anatomy Textbook, 40th Edition, 2008, Susan and Standring, pg.no415, 416,424,425,431.
- [2]. Essentials of Human anatomy,Part II, Asim Kumar Datta, 3rdEdition,Current books International,pg. 59,60,65.
- [3]. CUNNINGHAM'S manual of Practical Anatomy, Volume Three, Head and Neck and Brain, G.J.ROMANES, Oxford Medical Publications, Fifteenth Edition,1986,Reprinted,2011.(pg.6,10,79).
- [4]. Essentials of Clinical anatomy, Keith.L.Moore, 3rd Edition, 2001, Lippincott,Williams& Wilkins. (pg.830).
- [5]. Shifan Khandayn et al,Morphological and Morphometric Study of Jugular Foramen in South Indian Population, International Journal of Anatomy and Research, Int J Anat Res 2013;1(3):122-27. ISSN 2321- 4287.
- [6]. SturrockR.R: Variations in the structure of the jugular foramen of the human skull; Journal of Anatomy; 1988; 160: 227- 230.
- [7]. SM AkramHossainetal, Variations in the Structure of the Jugular Foramen of Human Skull, Bangladesh Journal of Anatomy July 2012, Vol. 10 No. 2 pp 45-49.
- [8]. Avanish Kumar, Ritu, Md.Jawed Aktar, Avanindra Kumar. Variations in Jugular foramen of human skull,Asian Journal of Medical Sciences,Mar-Apr 2015,Vol.6.Issue 2.
- [9]. Patel M.M. &Singel T.C.: Variations in the structure of the jugular foramen of the human skull in Saurashtra region; J. Anat. Soc. India; 2007; 56(2); 34-37.
- [10]. HussainSaheb S et al Morphological variations in the structure of the jugular foramen of the human skulls of south India, Biomedical Research 2010; 21 (4): 349-350.
- [11]. Sethi.R,Singh.V, KaulNV. Morphological variations of jugular foramen in North Indian human adult skulls,Indian J Otol 2011;17:14-6.

How to cite this article:

T.L.Anbumani, M.Raja, A.Thamarai Selvi. MORPHOLOGY AND MORPHOMETRIC STUDY ON ANATOMICAL VARIATIONS OF JUGULAR FORAMEN IN ADULT HUMAN SKULLS. Int J Anat Res 2019;7(2.1):6410-6415. DOI: 10.16965/ijar.2019.130