

A STUDY OF NUTRIENT FORAMINA OF DRY HUMERUS IN SOUTH INDIAN POPULATION

Savithri K ¹, Mekala D ^{*2}.

¹ Assistant Professor, Department of Anatomy, Coimbatore Medical College, Coimbatore, Tamil Nadu, India.

^{*2} Assistant Professor, Department of Anatomy, Coimbatore Medical College, Coimbatore, Tamil Nadu, India.

ABSTRACT

Background: Nutrient foramen is an opening in the bone shaft which allows passage to the blood vessels of the medullary cavity of a bone for its nourishment and growth. Knowledge about precise location and direction of the nutrient artery of long bones is important during any surgical or orthopaedic procedures of limbs, such as bone grafts and microsurgical vascular bone transplantations. This study was carried to record the number, situation and position of nutrient foramina in humerus of adults in south Indian population.



Materials and methods: The study was conducted on 85(Right-38, Left-47) humeri collected from Anatomy Department of Coimbatore Medical College, Coimbatore. Length of each humerus bone was measured with the help of osteometric board. With the help of hand lens bones were observed for the number, direction and location of nutrient foramen with respect to the surface and borders.

Results: In the present study majority of humerus bones have single nutrient foramen(64.7%) and mainly located on the anteromedial surface(51.7%) followed by medial border (36.5%) especially in the middle one third (87.1%) of the humerus.

Conclusion: This study may give precise knowledge about location and number of nutrient foramina which is important for orthopaedic surgeons during surgical procedures such as fracture repair, bone grafts and microsurgeries.

KEY WORDS: Humerus, nutrient foramina, South Indian Population.

Address for Correspondence: Dr. Mekala D, Assistant Professor, Department of Anatomy, Coimbatore Medical College, Coimbatore, Tamil Nadu, India. **E-Mail:** mekalavijayanand@gmail.com

Access this Article online	Journal Information
Quick Response code  DOI: 10.16965/ijar.2019.147	International Journal of Anatomy and Research ICV for 2016 90.30 ISSN (E) 2321-4287 ISSN (P) 2321-8967 https://www.ijmhr.org/ijar.htm DOI-Prefix: https://dx.doi.org/10.16965/ijar 
	Article Information
	Received: 13 Feb 2019 Peer Review: 14 Feb 2019 Revised: None
	Accepted: 13 Mar 2019 Published (O): 05 Apr 2019 Published (P): 05 Apr 2019

INTRODUCTION

Nutrient foramen is an opening in the bone shaft which allows passage to the blood vessels of the medullary cavity of a bone for its nourishment and growth[1]. One or two diaphyseal nutrient arteries enter the shaft obliquely through nutrient foramina which lead into nutrient canals. Their sites of entry and angulation are almost constant and characteristically

directed away from the dominant growing epiphysis [2]. The nutrient foramina in the long bones of human limbs are described as being directed towards the elbow and away from the knee. This is said to be due to one end of limb bones growing faster than the other [3].

Their positions in mammalian bones are variable and may alter during the growth phase. The topographical knowledge of these nutrient

foramina is useful in operative procedures to preserve the circulation [4]. The fractures of the long bones are increasing in number, due to an increase in the numbers of industrial and road traffic accidents, sports injuries and pathological fractures in osteoporotic victims. The non-union of a fractured bone can be a complication of a closed or an open reduction. When the blood supply is not established well, it can be complicated by a delayed union or a non-union of the fracture and this reveals that the medullary arterial system plays an important role in the revascularization of the necrosing cortex and the uniting callus of the fracture site [5].

Knowledge about precise location and direction of the nutrient artery of long bones with its common variations is of supreme importance during any surgical or orthopaedic procedures of limbs, such as bone grafts and microsurgical vascular bone transplantations [6]. This study was carried to record the number, situation and position of nutrient foramina in humerus of adults in south Indian population.

MATERIALS AND METHODS

The study was conducted on 85(Right-38, Left-47) humeri collected from Anatomy Department of Coimbatore Medical College, Coimbatore. Damaged bones and pathologically deformed bones were excluded from the study. All the adult humeri which were not necessarily paired and those of unknown age and sex were examined. The side determination was done for the entire humeri. The nutrient foramina were distinguished by the presence of a well-marked groove leading to the foramen, and by a well-marked often slightly raised edge of the foramen at the commencement of the canal. Length of each humerus bone was measured with the help of osteometric board. Bones were divided into three zones; Zone I – upper 1/3rd, Zone II – Middle 1/3rd and Zone III – lower 1/3rd. With the help of hand lens bones were observed for the number, direction and location of nutrient foramen with respect to the surface and borders.

Fig. 1: A photograph of humerus shows double nutrient foramina.



Fig. 2: A photograph of humerus shows triple nutrient foramina.

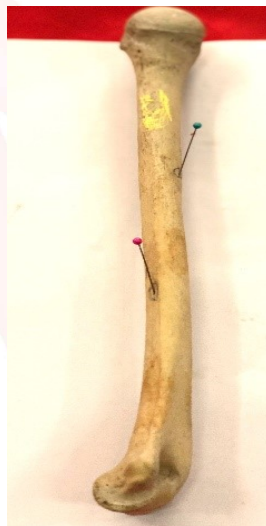
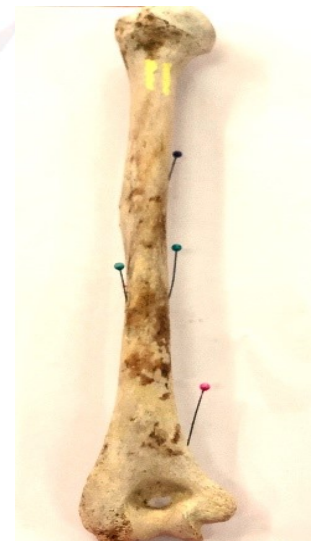
Fig. 3: A photograph of humerus shows quadruple nutrient foramina.



RESULTS

The following observations were found to conclude the results of the study.

Table 1: Number of nutrient foramen on humerus.

Number of nutrient foramen	Right (n=38)		Left (n=47)		Total (n=85)
	number	percentage	number	Percentage	percentage
0	3	7.9	1	2.1	4.7
1	25	65.8	30	63.8	64.7
2	9	23.7	12	25.5	24.7
3	1	2.6	2	4.3	3.5
4	0	0	2	4.3	2.4
Total	38	100	47	100	100

Table 2: Location of nutrient foramen on humerus.

Location of nutrient foramen	Right (n=38)		Left (n=47)		Both (n=85)	
	Number	Percentage	Number	Percentage	Number	Percentage
Medial border	14	36.8	17	36.2	31	36.5
Anterior border	0	0	0	0	0	0
posterior border	0	0	0	0	0	0
Anteromedial surface	21	55.3	23	48.9	44	51.7
Anterolateral surface	2	5.3	3	6.4	5	5.9
Posterior surface	1	2.6	4	8.5	5	5.9

It has been concluded that 64.7% of the humeri had a single nutrient foramen. The double foramen was observed in 24.7% of the humeri. Triple foramen was found in 3.5% of the humeri and 2.4% of humeri had four nutrient foramina where as 4.7% humeri did not have any foramina.

It was concluded that the majority (51.7%) of the nutrient foramina were found to be present on the antero-medial surface of the shaft of humeri, followed by 36.5% of the nutrient foramina were concentrated on the medial border and each 5.9% of the nutrient foramina were located on the posterior surface and anterolateral surface of the shaft of humeri.

Table 3: Location of nutrient foramen with respect to the zones of Humerus.

Zones	Right		Left		Total	
	n	%	n	%	N	%
Zone I	0	0	0	0	0	0
Zone II	34	90	40	85.1	74	87.1
Zone III	4	11	7	14.9	11	12.9

Overall incidence of presence of nutrient foramina in the middle one-third or Zone II of the shaft of humeri were 87.1%, followed by the lower one-third or Zone III 12.9% and there was no nutrient foramina observed in upper one-third or zone I.

Direction of foramina: The direction of nutrient foramina was not showing any deviation from normal anatomical feature even in single case throughout the study. All the foramina were directed downward or toward the lower end of humeri.

DISCUSSION

During the active growth of long bones the nutrient artery is a principle source of blood. The humerus also received blood supply from other sources like metaphyseal and periosteal arteries which are branches of axillary and brachial

artery. The periosteal and the metaphyseal arteries supply the outer cortex and the metaphysis of the bone, but the inner half of the cortex and the medulla of the shaft are predominantly dependent on the nutrient artery [7].

The constancy of the main nutrient artery to humeral diaphysis is remarkable. The danger of damaging this artery is greatest in open reduction of the fracture involving the mid-shaft region of the bone [12].

The study on the blood supply of the shaft will help in knowing about the healing of fractures, delayed unions and non-unions of the bone following fractures and bone transplants [13].

Number of foramina: The present study showed that single nutrient foramen was present in 64.7% of humeri which was similar to the findings observed by Mansur DI et al who reported 60.87% [9]. A study done by Bhavana Khandve et al . in Chhatisgarh state observed that 70% of humeri had a single nutrient foramen[1]. Similar studies conducted by Arvind Kumar Pankaj et al [7] who reported 80.86% and Shanta Chandrasekaran et al [8] reported 76.74% incidence of single nutrient foramen. The incidence was found to be higher in a study conducted by Kalpana Thounaojam et al. who reported that the incidence of 84% of humeri with single nutrient foramen as compared to the present study[10]. Similarly the study conducted by Ashrani S K et al reported the incidence of 87% humeri with single nutrient foramen [11]. In the present study double nutrient foramen was present in 24.7% of humeri which was almost similar to the findings observed by Mansur DI et al [9] 28.85% ,Bhavana Khandve et al .[1] in Chhatisgarh state 29% and Shanta Chandrasekaran et al [8] 20.54% of humeri. In contrast to the present study, Ashrani S K et al [11] reported 11%, Kalpana Thounaojam et al

[10] observed 16% and 13.42% of double nutrient foramen observed by Arvind Kumar Pankaj et al [7].

The present study showed that triple nutrient foramina was present in only 3.5% of humeri. Similar studies done by Mansur DI et al [9] and Shanta Chandrasekaran et al [8] who reported the frequency of three foramina was 6.32% and 2.71% , whereas findings reported by Arvind Kumar Pankaj et al [7] was 0.29%. A similar study done by Kalpana Thounaojam et al.[10] didn't observe (0%)triple nutrient foramen in their study.

The present study also reported that quadruple nutrient foramina were present in 2.4% of humeri which were almost similar to the study conducted by Mansur DI et al [9] who reported 1.98% of humeri with four nutrient foramina. Not many authors had observed the presence of quadruple nutrient foramina in the humeri.

In the present study, it has been also observed that 4.7% of humeri did not have nutrient foramen. According to the study of Ashrani S K [11] et al on dry humeri, 2% didn't have nutrient foramen. Bhavana Khandve et al [1] in their study reported that absence of nutrient foramen in 3% of humeri. A higher incidence(19%) of absence of nutrient foramen was reported by Arvind Kumar Pankaj et al [1]. Absence of nutrient foramen in long bones is well known. In such cases, bones are supplied by periosteal arteries.

However, most of the authors in their study agreed that the majority of humeri had a single nutrient foramen at a higher incidence.

Location of foramina: The position of nutrient foramen is not constant. Location of foramina may vary. The danger of damaging this artery is greatest in open reduction of the fracture involving the mid-shaft region of the bone [10]. In the present study the situation of nutrient foramen in relation to different surfaces and borders of humerus was noted.

The maximum number of foramen was found on anteromedial surface (51.7%) followed by medial border (36.5%). Bhavana Khandve et al [1] , Arvind Kumar Pankaj et al [7] and Shanta Chandrasekaran et al [8] also reported the higher incidence of nutrient foramina situated

on the antero-medial surface of the shaft of the humeri.

In contrast to present study Ashrani S K et al[11] reported the higher incidence of location of nutrient foramina in medial border (57%) followed by anteromedial surface (43%).

The present study also concluded that 5.9% of nutrient foramina were located on the antero-lateral surface and 5.9% on posterior surface. Similar study was conducted by Mansur DL et al [9]. reported 4.62% of nutrient foramina on antero-lateral surface and 6.52% on posterior surface which were almost similar to the results of present study. A similar study done by Kalpana Thounaojam et al [10]. observed 6% each in anterolateral and posterior surface. However, a study conducted by an Shanta Chandrasekaran et al [8] observed the higher incidence (22%) of the presence of nutrient foramina on posterior surface than the present result. Arvind Kumar Pankaj et al [7]. reported 12.11% of foramina on posterior surface and 3.16% on anterolateral surface in North Indian population which was contrast to the present result.

Location of nutrient foramen in respect to zone of humeri: The present study showed that the majority of nutrient foramina (87.1%) were found to be present on zone II (the middle one-third) and 12.9% were on zone III (lower one third) of the shaft of the humeri which was correlated with the study conducted by Shanta Chandrasekaran et al [8]. who reported 86.43% of nutrient foramina on the middle one third of humeri and 13.57% on the lower one third. A study conducted by Mansur DL et al [9]. found that 94.84% of the nutrient foramina were located on the middle one-third of the humeri and a similar trend also reported by Arvind Kumar Pankaj et al (97.63%) and Kalpana Thounaojam et al (94%) which were higher than the present result [7],[10].

Direction of foramina: Many studies had been conducted to observe the direction of nutrient foramina in humeri to determine that whether it follows the law of ossification or not [9].

The present study observed that the direction of all the nutrient foramina of humeri was directed towards the lower end of humeri which was supported by many studies.

CONCLUSION

The study concluded that majority of humerus bones have single nutrient foramen and mainly located on the anteromedial surface especially in the middle one third of the humerus. The knowledge about location and number of nutrient foramina is important for orthopaedic surgeons during surgical procedures such as fracture repair, bone grafts and microsurgeries.

Conflicts of Interests: None

REFERENCES

- [1]. Bhavana Khandve, Ambrish Verma. A Study of Nutrient Foramina of Humerus at Chhattisgarh State, International Journal of Innovative Research in Medical Science;2018; 3(3):1794-1798.
- [2]. Standring Susan. Gray's Anatomy- The Anatomical Basis of Clinical Practice. Functional anatomy of the muscular system. 39th edition, Elsevier Churchill Livingstone. Edinburgh, London; 2005: p 95.
- [3]. Mysorekar VR. Diaphysal nutrient foramina in human long bones. J Anat. 1967;101(4):813-22.
- [4]. Veeramuthu. M, Elangovan. M, Manoranjitham. Nutrient Foramina: A study in the long bones of human upper extremities. International Journal of Anatomy and Research;2017;5(3.3):4394-99.
- [5]. A. Bharathi, V.Janaki, Gouri T.L.S, Archana. Morphometric Variations of Nutrient Foramen in Adult Human Humerus in Telengana Region. IOSR Journal of Dental and Medical Sciences;2016; 15(4):43-46.
- [6]. Solanke KS, Bhatnagar R, Pokhrel R. Number and position of nutrient foramina in humerus, radius and ulna of human dry bones of Indian origin with clinical correlation. OA Anatomy; 2014;2(1):4.
- [7]. Arvind Kumar Pankaj¹, Rakesh Kumar Verma, Archana Rani, Anita Rani, Navneet Kumar. Morphometric study of nutrient foramina of humerus in North Indian population. Indian Journal of Clinical Anatomy and Physiology; 2017;4(2):169-172.
- [8]. Shanta ChandraSeKaran, Shanthi KC, A Study on the Nutrient Foramina of Adult Humerii. Journal of Clinical and Diagnostic Research; 2013 June; Vol-7(6): 975-977.
- [9]. Mansur DI, Manandhar P, Haque MK, Mehta DK, Duwal S, Timalisina B. A Study on Variations of Nutrient Foramen of Humerus with its Clinical Implications. Kathmandu Univ Med Journal; 2016;53(1):78-83.
- [10]. Kalpana Thounaojam, Subhalakshmi Wahengbam, Elizabeth Remei. Diaphyseal nutrient foramina in human adult humerus. Int J Anat Res 2016;4(4):3036-3039.
- [11]. Asharani S K, Ajay Ningaiah. A study on the nutrient foramen of humerus. Int J Anat Res 2016;4(3):2706-2709.
- [12]. Bucholz RW, Brown CMC, Heckman JD, Tornetta P, McQueen MM, Ricci WM. Bone and joint healing. In: Buckwalter JA, Einhorn TA, Marsh JL, Gulotta L, Ranawat A, Lane J, editors, Rockwood and Green's Fractures in Adults. 7th edition. Philadelphia: Lippincott Williams and Wilkins, 2010; 1:90.
- [13]. Robert WA. A physiological study of the blood supply of the diaphysis. J Bone Joint surg. 1927; 9: 153-54.

How to cite this article:

Savithri K, Mekala D. A STUDY OF NUTRIENT FORAMINA OF DRY HUMERUS IN SOUTH INDIAN POPULATION. Int J Anat Res 2019;7(2.1):6474-6478. DOI: 10.16965/ijar.2019.147