

COMPARATIVE MORPHOLOGICAL AND MORPHOMETRICAL ANALYSIS OF HUMAN AND PORCINE MITRAL VALVE

Supadevi Sundarasamy ^{*1}, Monica Diana ², N. Manimozhian ³, S. Supasakthi ⁴.

^{*1} Assistant professor, Government kilpauk medical college, Chennai, Tamil Nadu, India.

² Assistant Professor, Karuna Medical College and Hospital, Vilayodi, Chittur, Palakkad District, Kerala, India.

³ Consultant Paediatrician, Mrithun Child Care Clinic, Mugalivakkam, Chennai, India.

⁴ Consultant Pathologist, Kongunad Hospital, Tatabad, Coimbatore, India.

ABSTRACT

Introduction: There is increased incidence of heart valve diseases in recent years due to life style modifications. The mortality rates in the heart valvular diseases are kept in pace using various modes of treatments. One such treatment is valve replacement surgery. It's done either by using mechanical valve prosthesis or tissue grafts. The tissue valves prosthesis, harvested from porcine heart are called as xenograft and are increasingly used in valve repair surgeries. In the present scenario, there is less number of systematically analysed literatures available on the comparative anatomy of human and porcine heart valves. Hence this study was carried out to acquire knowledge and to put forth some points to future research works on heart valves.

Materials and methods: In this study, 20 formalin fixed porcine and human hearts were procured from slaughter house and cadavers respectively. The morphology and morphometry of mitral valve were observed and analysed using spss software 20 version. All the dependent variables were compared using student t test and independent sample test.

Observation and results: it was observed that the mean circumference of the human mitral valve was 82.31mm and that of the porcine was 78.79 mm. The rough zone and clear zone was more prominent in porcine heart valves than the human heart valves. It was observed that the mitral valve of the porcine resembles the human heart valve in morphology and morphometrical values were coinciding to their maximum.

Conclusion: The porcine valve resembles human heart valves in morphology and it can be used in designing valve substitutes in replacement surgeries. Porcine valve can also be used as bio-prosthesis by matching the morphometry and by reducing the geometrical difference to their minimum by using any modes of interventional radiology.

KEY WORDS: tissue graft, porcine, mitral valve, morphometry.

Address for Correspondence: Dr. Supadevi Sundarasamy, P6c2b, La Celeste Apartment, Nethaji Street, Madananthapuram Main Road, Mugalivakkam, Chennai, Tamilnadu-600125, India.

E-Mail: supadevi.dr@gmail.com

Access this Article online	Journal Information
Quick Response code  DOI: 10.16965/ijar.2019.191	International Journal of Anatomy and Research ICV for 2016 90.30 ISSN (E) 2321-4287 ISSN (P) 2321-8967 https://www.ijmhr.org/ijar.htm DOI-Prefix: https://dx.doi.org/10.16965/ijar 
	Article Information
	Received: 29 Mar 2019 Peer Review: 29 Mar 2019 Revised: None
	Accepted: 06 May 2019 Published (O): 05 Jun 2019 Published (P): 05 Jun 2019

INTRODUCTION

Heart valve diseases are increasing worldwide due to various pathological conditions like rheumatic fever, endocarditis and leading to valve prolapse, narrowing of valve and calcification of heart valves causing either valve

incompetence or regurgitation. The heart valvedisease progresses to a point that treatment by medicines does not provide symptomatic relief for the patients. In ir-reversible damage, surgery to repair the valve or replacement of valve becomes the best alternative. In

replacement surgeries, the choice is more likely between carbon based mechanical valve or biological tissue valve. In tissue valves prosthesis, the tissue valve is procured from homograft or xenograft. Xenograft tissue valves are harvested from porcine heart. There is an increasing popularity of mitral valve repair in tissue replacement surgeries and there is a current interest on the homograft and heterograft, warranting a new look at the normal functional anatomy of the systems [1].

This study is conducted to bridge the knowledge gap in the field of valvular anatomy and to enhance the similarity in morphological and morphometrical features of human heart valves and porcine heart valves.

METHODOLOGY

The human and animal ethical committee clearance has been obtained and the study was carried out. A total number of 20 human heart valves were compared with 20 porcine heart valves. The materials used were vernier caliper, blotting paper, surgical silk thread and scissors.

Porcine heart was obtained from slaughter house and was fixed in 10 % formal saline solution. The formalin fixed human heart specimens were procured from the embalmed cadavers, from the department of anatomy in Sri Ramachandra Medical College and Research Institute.

The left atrial wall was removed to expose the mitral valve. To obtain the circumference and the length of the attached margin, the surgical silk thread was used on the atrial aspect as illustrated in figure 1 and 2. The height of the leaflet was measured using vernier caliper. The rough zone and clear zone were observed and measured on the atrial aspect using transillumination technique as illustrated in figure 3 and 4.

Both the human hearts and porcine hearts weight ranging from 300 gm – 450 gm was used and any deviation from normal were excluded. Total annular circumference of the valve, annular length, height of each leaflet, height of the rough zone and clear zone were observed. All the dependent variables were compared using student t test and independent sample test.

Fig. 1: Human mitral valve (atrial aspect).

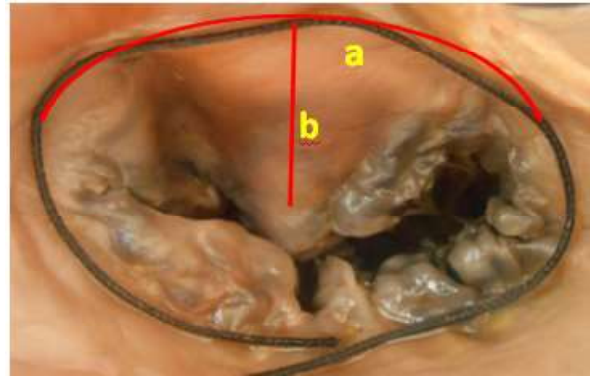
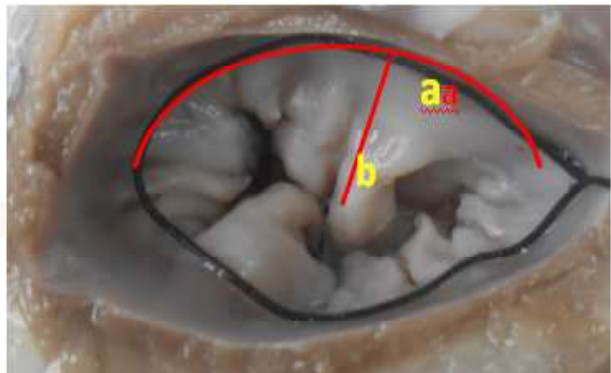


Fig. 2: Porcine mitral valve (atrial aspect).



In figure 1 & 2: a: attached margin of the mitral valve, b: height of the leaflet from the attached margin to the free margin

Fig. 3: Human mitral valve (atrial aspect).

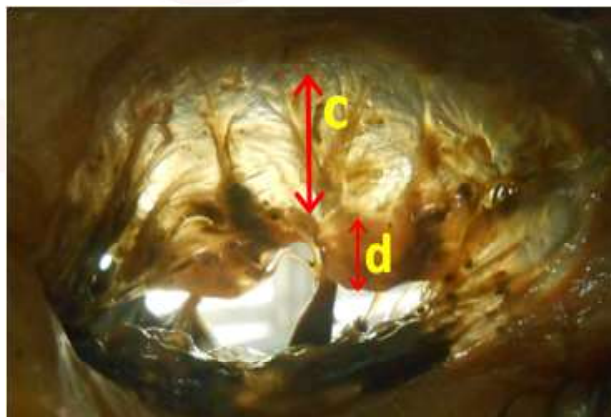


Fig. 4: Human mitral valve (atrial aspect).

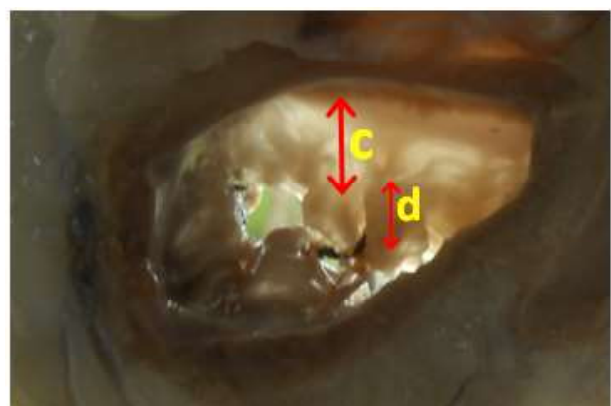


fig 3 & 4: c: height of the rough zone, d: height of the clear zone

RESULTS

Height, Length, Rough Zone And Clear Zone Of The Mitral Valve Of Human And Porcine.

	Group	N	Mean	Std. Deviation	Std. Error Mean
CIRCUMFERENCE OF HUMAN MITRAL VALVE	Human	20	82.3190	18.31201	4.09469
	Porcine	20	78.7945	23.81411	5.32500
Attached margin of the anterior leaflet	Human	20	29.0200	6.41380	1.43417
	Porcine	20	31.5530	11.34090	2.53590
Attached margin of the posterior leaflet	Human	20	38.7625	11.16654	2.49692
	Porcine	20	40.0045	10.55644	2.36049
height of the anterior leaflet	Human	20	16.2655	3.06329	.68497
	Porcine	20	15.6340	3.60834	.80685
height of the posterior leaflet	Human	20	12.1960	4.01588	.89798
	Porcine	20	14.8130	3.87642	.86679
Rough zone of anterior leaflet	Human	20	6.5605	1.94076	.43397
	Porcine	20	8.2790	2.61481	.58469
Rough zone of posterior leaflet	Human	20	6.1215	2.39543	.53563
	Porcine	20	7.4850	2.22066	.49655
Clear zone of anterior leaflet	Human	20	9.7625	3.25097	.72694
	Porcine	20	7.9285	2.17062	.48536
Clear zone of posterior leaflet	Human	20	5.7380	2.61504	.58474
	Porcine	20	7.7015	2.57398	.57556

DISCUSSION

The human mitral valve: The human mitral valve anatomy was observed and the circumference was 82.3 mm. In the present study the length of the attached margin of the anterior and posterior cusp was 29.02 mm and 38.76 mm and it correlated to minimum with a study, where only length of the leaflets was observed [2]. The mitral ring was biconcave when seen from atrial aspect [3]. The mitral valve leaflet was more d shaped than the circular shape portrayed by the prosthetic valve [4] and the mitral valve annulus was a rigid fibrous ring [5]. The mitral valve leaflets free edges were split by indendation and none of it reaches the mitral ring. The annular attachment of the anterior leaflet was half that of the posterior leaflet and the anterior leaflet was almost twice deep as the posterior one [6,7]. The anterior cup was bi-scalloped and the posterior cusp had a crescent shape. The free border was notched [3] and resembles a cone shaped structure when the valve cusp margins were in contact and kidney shaped when valve is closed.

The commissural area had distinct central portion which was clear on trans-illumination while the periphery merged with the leaflet. The leaflet had on its atrial surface, a distinct ridge that followed the rim of the leaflet and distal to

this was the rough zone of the leaflet and this was opaque on trans-illumination. Between the rough zone and the valve annulus was the thin membranous clear zone which was clear on trans-illumination. At the centre of the anterior leaflet, the clear zone was approximately twice the height of the rough zone [8]. The posterior leaflet has a narrow clear zone.

Porcine mitral valve: The porcine mitral valve apparatus consists of fibrous ring, cuspids, tendon cords and papillary muscles [9]. The mean circumference of the mitral valve was 78.79 mm and the length of the anterior and posterior leaflet was 29.02 mm and 38.76 mm. The height of the anterior and posterior leaflet was 16.26 mm and 12.19 mm. The mean width of the septal cuspid was 25.4 mm, and parietal cuspid was 15.5 mm. The height of the septal cuspid and parietal cuspid was 19.8 mm and 15.2 mm and the septal cuspid was large [10].

The demarcation between the rough zone and clear zone was prominent in porcine heart valves even without trans-illumination. The height of the rough zone and clear zone of the anterior and posterior leaflet was 8.2 mm, 7.92 mm and 7.48 mm and 7.70 mm.

In this study, it was also observed that the ventricular walls were much thicker than the human ventricular wall. The cuspids were also

showing varying thickness compared to the human mitral valve cusps which were observed well during analysis of rough zone and clear zone on Tran's illumination.

CONCLUSION

The morphology of the human and porcine heart valve shared excellent features and they can be preferred in designing of the mitral and tricuspid valve substitutes and tissue engineering techniques in valve replacement surgeries. Although the morphometric differences are observed, this can be reduced to minimum by prior matching of the replacement valve with the tissue prosthesis to reduce the mismatching to the bare minimum.

Conflicts of Interests: None

REFERENCES

- [1]. Kunzelman K.S, Cochran R.P, Verrier E.D and Eberhart R.C Anatomic basis for mitral valve modelling. J. Heart valve Dis. 1994a;3(5):491-6.
- [2]. Brock. R. C. The surgical and pathological anatomy of the mitral valve. Brit. Heart j. 1952;14:489-512.
- [3]. Van Der Spuy. J. C. The Functional and Clinical Anatomy of the Mirtal Valve. Brit Heart J, 1958;20:471-478.
- [4]. Ho. S.Y. Anatomy of the mitral valve. Heart 2002;88(suppl iv):iv5- iv 10.
- [5]. Karen P. Mccarthy, Liam Ring and Bushra S. Rana. Anatomy of the mitral valve: understanding the mitral valve complex in mitral regurgitation. European journal of echocardiography 2010;11:i3-i9.
- [6]. Ranganathan N, J. H. C. Lam, E.D. Wigle and M.D.Silver. Morphology of the human mitral valve II-The valve leaflets. Circulation 1970;41:459- 467.
- [7]. Morris E. W. T. Some features of the mitral valve. Thorax 1960;15:70-73.[8]. Louis A. Du Plessis and Paul Marchand. The anatomy of the mitral valve and its associated structures. Thorax 1964;19:221-227.
- [9]. Lima, JVS., Almeida, J., Bucler, B., Alves, RP., Pissulini et al. Anatomy of the left atrioventricular valve apparatus in landrace pigs. J. Morphol. Sci; 2013;30(1):63-68.
- [10]. Simon J. Crick, Mary N. Sheppard, Siew Yen Ho, LiorGebstein and Robert H. Anderson. Anatomy of the pig heart: comparisons with normal human cardiac structure. J. Anat. 1998;193:105-119.

How to cite this article:

Supadevi Sundarasamy, Monica Diana, N. Manimozhian, S. Supasakthi. COMPARATIVE MORPHOLOGICAL AND MORPHOMETRICAL ANALYSIS OF HUMAN AND PORCINE MITRAL VALVE. Int J Anat Res 2019;7(2.3):6632-6635. DOI: 10.16965/ijar.2019.191