

# VARIATIONS OF THE NUTRIENT FORAMINA IN DRIED HUMAN FEMUR

Raveena Paul GR <sup>1</sup>, Immanuel Navin Kumar Balla <sup>\*2</sup>, Sreelatha S <sup>3</sup>, Rajasree TK <sup>4</sup>, Krupa SailajaT <sup>5</sup>.

<sup>1</sup> Assistant Professor, Department of Anatomy, Malla Reddy Institute of Medical Sciences, Suraram, Hyderabad, Telangana, India.

<sup>\*2</sup> Associate Professor, Department of Anatomy, Malla Reddy Institute of Medical Sciences, Suraram, Hyderabad, Telangana, India.

<sup>3</sup> Professor, Department of Anatomy, Malla Reddy Medical College for Women, Hyderabad, Telangana, India.

<sup>4</sup> Professor and Head, Department of Anatomy, Malla Reddy Institute of Medical Sciences, Suraram, Hyderabad, Telangana, India.

<sup>5</sup> Associate Professor, Department of Anatomy, Maheshwara Medical College and Hospital, Chitkul (V), Near Isnapur X Roads, Patancheru, Telangana, India.

## ABSTRACT

**Background:** An understanding of the location, number, direction and size of nutrient foramina in long bones is very important clinically, especially in orthopaedic surgical procedures such as fracture repair, bone grafting, vascularized bone microsurgery, intramedullary reaming and plating, as well as in medico legal cases. An accurate knowledge of the location of the nutrient foramina in long bones should help prevent intraoperative injuries in orthopaedic, as well as in plastic and reconstructive surgery.

**Aims & Objectives:** The aim of our study is to observe the variations in number, location, direction and size of the nutrient foramina of Dried Human Femur.

**Materials and Methods:** The study comprised 200 dry normal adult femur bones of unknown sex obtained from the Department of Anatomy of various medical colleges of Telangana, India.

**Results:** The total number of nutrient foramina obtained in 200 femurs was 326. 82 bones had single nutrient foramen (41%), 111 bones had double nutrient foramina (55.5%), 6 bones had triple nutrient foramina (3%), and only 1 bone 4 nutrient foramina (0.5%) and none of the bones showed zero foramen. The size of nutrient foramina were also noted in 200 bones, 60 bones presented small sized foramina (18%), 130 bones presented with medium sized foramina (40%), and rest of 136 bones presented with large sized foramina (42%). The nutrient foramina obeyed the general rule that is, directed away from the growing end of the bone. Among 326 nutrient foramina 149 were located on posterior surface (46%), about 126 foramina were located on medial surface (38.50%), 38 were located on the lateral surface (12%), and the remaining 12 were located on the popliteal surface (6%), and none on the anterior surface.

**Conclusion:** Knowledge of the localization and number of the nutrient foramina is useful in certain surgical procedures such as bone grafting and microsurgical vascularized bone transplantation, to preserve the circulation intact and for open reduction surgeries.

**KEY WORDS:** Femur, Nutrient Foramina, Nutrient Artery, Posterior surface.

**Address for Correspondence:** Dr. B. I. Navin Kumar, Associate Professor, H.No: 2-6/2, Gowthami Nagar Colony, Chandanagar, Hyderabad, Telangana. 500050, India. Mobile No: 9490320825

**E-Mail:** [immanuel.navin@gmail.com](mailto:immanuel.navin@gmail.com)

Access this Article online	Journal Information
<b>Quick Response code</b>  <b>DOI:</b> 10.16965/ijar.2019.224	<b>International Journal of Anatomy and Research</b> ICV for 2016 90.30 ISSN (E) 2321-4287   ISSN (P) 2321-8967 <a href="https://www.ijmhr.org/ijar.htm">https://www.ijmhr.org/ijar.htm</a> DOI-Prefix: <a href="https://dx.doi.org/10.16965/ijar">https://dx.doi.org/10.16965/ijar</a> 
	Article Information
	Received: 09 May 2019 Peer Review: 09 May 2019 Revised: None
	Accepted: 10 Jun 2019 Published (O): 05 Jul 2019 Published (P): 05 Jul 2019

## INTRODUCTION

Femur is the typical, longest, weight bearing bone of the body and is supplied by four groups of arteries such as nutrient artery, epiphyseal arteries, metaphyseal and periosteal arteries. Among them nutrient artery is the principal source of blood supply to a long bone and is particularly important during active growth period and early stages of ossification [1]. Therefore, they play a very significant role in healing of fractures and prevention of avascular bone necrosis. Despite the fact that the metaphyseal, epiphyseal and periosteal vessels maintain the blood supply of bones, after an interruption of nutrient arteries, it cannot support the complete healing of the fractured bones. Injury to the nutrient artery at the time of fracture, or during subsequent manipulation and surgery may be a significant predisposing factor to a faulty union of long bones [2].

The nutrient foramen in femur is directed proximally usually towards the linea aspera. The main nutrient artery is usually derived from the second perforating artery, branch of profunda femoris artery. If two nutrient arteries occur, they may branch from the first and third perforators [3].

Nutrient foramen is the cavity, which conveys the nutrient arteries and the peripheral nerves to the bone. They are distinguished by the presence of a marked groove leading to the foramen and by a marked, often slightly raised edge of the foramen. Nutrient foramen leads into a canal, which is directed obliquely [4]. It was first described by Berard in French as "Au coudejem' appuis, du genou je m'enfuis" which means "To elbow I go, from the knee I flee". This is called Berard's rule of canal direction [5]. The growing end is a misnomer, because both the ends of a long are growing, so it should dominant growing end of a long bone. Nutrient artery may be single or double. When two nutrient arteries are present they are not necessarily of equal size [6]. When two nutrient arteries are present, the ascending and descending branches were derived from separate origin [7]. During a bone graft surgery, the vascularisation of the remaining bones has to be considered with the vascularity of this area allowing various options in grafting. The bony defect which is left behind

following traumatic injuries, tumor resection procedures and pseudo arthrosis can all be reconstructed by bone grafting procedures and the preferred modality is free vascularised bone graft [8].

The objective of the investigation was to contribute details of the diaphyseal nutrient foramina of the femur, specifically in terms of location, number, size and direction.

## MATERIALS AND METHODS

The present study was undertaken on 200 dry normal adult femur bones of unknown sex obtained from the Departments of Anatomy, Gandhi Medical College, Secunderabad; Osmania Medical College, Hyderabad; Deccan College of Medical Sciences, Hyderabad; and SVS Medical College, Mahabubnagar, for a period of 2yrs.

Nutrient artery number, size and direction were noted. The size of the nutrient artery was observed by using 21, 22 and 26 size gauge needles and categorized into 3 groups.

1. Small 0.45 to 0.70mm which admitted 26 gauge needle
2. Medium 0.71 to 0.80 mm which admitted 22 gauge needle
3. Large > 0.81mm which admitted 21 gauge needle.

## RESULTS

### Regarding the Number of Nutrient foramina:

Among the 200 femurs studied 326 nutrient foramina, 82 bones had single nutrient foramina (41%), 111 bones had double nutrient foramina (55.5%), 6 bones had triple nutrient foramina (3%), and only 1 bone 4 nutrient foramina (0.5%) and none of the bones showed zero foramen.

### Regarding the Size:

The size of nutrient foramina were studied in 200 bones, 60 bones presented small sized foramina (18%), 130 bones presented with medium sized foramina (40%), and rest of the bones i.e., 136 bones presented with large sized foramina (42%).

Out of 111 femora with double foramina, 90 had different sized foramina, 21 had same sized nutrient foramina, in which 8 had same small size, 7 had same medium size, and 6 had same large size foramina.

6 femora had triple nutrient foramina, 1 had 3 different sized foramina, 3 had 1 small and 2 large sized foramina, and 1 had 2 small sized and 1 medium sized foramina, and 1 had 1 medium and 2 large sized foramina.

1 femur with 4 nutrient foramina had 3 small sized and 1 medium sized foramina

**Regarding the Location:** In this study the foramina location was studied in relation to the surfaces of the femur. Out of 326 nutrient foramen, about 149 were located on posterior surface (46%), about 126 foramina were located on medial surface (38.50%), 38 were located on the lateral surface (12%), and the remaining 12 were located on the popliteal surface (6%), and none on the anterior surface.

**Regarding the Direction:** All the nutrient foramina were directed upwards, away from the knee joint.

**Photograph 1:** A single nutrient foramen on the posterior surface of femur, with its groove and the raised edge for the nutrient artery.



**Photograph 2:** Femur with 2 nutrient foramina, one smaller sized on the medial surface and the other medium sized on the posterior surface.



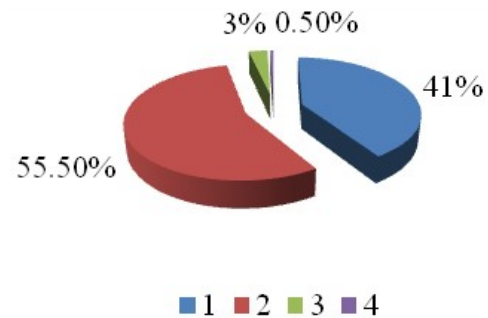
**Photograph 3:** Femur with 2 nutrient foramina, one smaller sized on the posterior surface and the other medium sized on the medial surface.



**Table 1:** Showing the number of nutrient foramina.

Total No. of Nutrient Foramina	Total No. of Femurs	Percentage
1	82	41%
2	111	55.50%
3	6	3%
4	1	0.50%

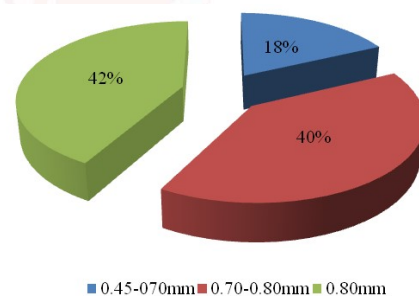
**Pie diagram 1:** Depicting the number of nutrient foramina.



**Table 2:** Showing the size of nutrient foramina.

Size of Nutrient Foramina	Total No. of Femur	Percentage
0.45-0.70mm	60	18%
0.71-0.80mm	130	40%
>0.81mm	136	42%

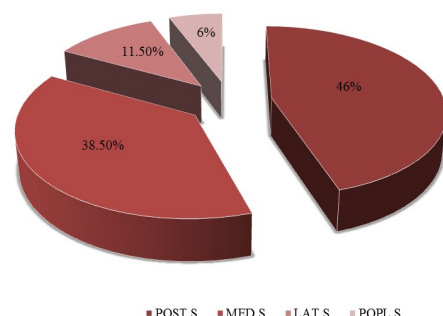
**Pie diagram 2:** Depicting the size of nutrient foramina.



**Table 3:** Showing the location of nutrient foramina on different surfaces of Femur.

Size of Nutrient Foramina	Total No. of Foramina	Percentage
POST S	149	46%
MED S	126	38.50%
LAT S	38	11.50%
POPL S	12	6%

**Pie diagram 3:** Depicting the location of nutrient foramina on different surfaces of the Femur.



## DISCUSSION

The arrangement of the diaphyseal nutrient foramina in the long bones usually go along a definite pattern. There are often two nutrient foramina in the femur and the humerus whereas in the other bones they are normally single. In the femur the nutrient foramina are restricted to the linea aspera or its immediate neighborhood in the middle third of the bone. One or two main diaphyseal nutrient arteries enter the shaft obliquely through nutrient foramina leading into nutrient canals. Their sites of entry and angulation are almost constant and characteristically directed away from the dominant growing epiphysis. This is the basis of the Growing-end hypothesis [9].

The present study showed single nutrient foramen in femur in 41% of cases which are correlating with Mysorekar VR who identified as 45% [10], Bridgeman G et al identified 44.03% [11], Bokariya P et al identified 45.2% [12], Prashanth KU et al observed 47.7%<sup>8</sup>, Murali Krishna Set al observed 42.09 % of single foramina [13], but Pereira GAM et al showed as high as 97.4% of cases [14].

The double nutrient foramina were 55.5% in present study. Mysorekar VR observed 50% [10], Li Mingyang et al identified 57% [15], and Qin Yueqin et al observed 54.07% [7], Forriol F et al identified 60% [16], Bridgeman.G et al identified 53.2% [11], Murali Krishna S et al identified 50.62% of double nutrient foramen [13] but Pereira GAM et al identified 34.9% [14].

Triple nutrient foramen is seen in 3% of femurs in the present study correlating with Prashanth KU et al 3.5% [8] but Pereira GAM et al observed 1.3% [14], Mysorekar VR identified 1.66 % [10], Murali Krishna S et al observed 7.49% of triple nutrient foramina [13] and four nutrient foramina in present study was 0.5% coinciding with Murali Krishna S et al 1.785% [13]. None of the femurs showed any nutrient foramina.

This signifies that most commonly femur has 2 nutrient foramina and the nutrient artery usually comes from the first and third perforating arteries of profunda femoris. Longitudinal stress fractures are more commonly with the lower limb bones. These arise either from the nutrient foramen or its superomedial aspect.

Hence, location, number and direction of nutrient foramina are important [3].

In the present study, among 200 femora 326 nutrient foramina were observed, out of which 150 (46%) were located on the posterior surface, 126 (38.50%) were on the medial surface, 38 (11.50%) on the lateral surface, and 12 (6%) on the popliteal surface and none on the anterior surface. This was well correlating with Mysorekar VR (48%) [10], Forriol F et al [16] and Sendemir E et al (41.2%) [17] who found nutrient foramina were located between the lips of the linea aspera, which is the posterior surface of the femur.

Whereas Prashanth K U et al in 2011, found the nutrient foramina were located in linea aspera in 52.3% bones, on medial surface in 12.6% and 0.79% each on lateral and popliteal surfaces [8]. Pereira GAM et al, obtained 80.9% on Linea aspera, 18.6% on lateral surface, 0.46% on medial surface [14].

Nurcan Imre identified 65% nutrient foramina in the middle third of the femoral diaphysis [18].

Erika Collipal et al analyzed 50 femora, in which 72.5% of nutrient foramina were located on the linea aspera, 21.25% on the medial surface, and 6.25% on the lateral surface [19] which were not well correlating with the present study.

The nutrient foramina were located on variable anatomical parts (surface and borders) of the femur and the most common location is on the posterior surface, including the linea aspera. Two well-known factors may affect nutrient foramen position. These are growth rates at two ends of the shaft and bone remodeling. Nutrient arteries which are the main blood supply to long bones are particularly vital during the active growth period and at the early phases of ossification. So the nutrient arteries should be kept patent until the growth is completed and even after the growth [8].

Mysorekar VR [10], Bridgeman G et al [11], Al Motabagani MAH [6], Prashanth KU et al [8], stated that the nutrient foramina is directed away from the knee joint directed above and was away from the knee. In the current study, all the 326 (100%) nutrient foramina were directed obliquely upwards in 200 femora, i.e., away from the dominant growing end.



Variations in the direction of nutrient foramina have been observed in many tetrapods and there is some similarity in the foraminal pattern in mammals and birds. Schwalbe explained that growth at the two ends of a long bone before the appearance of the epiphyses is equal. Hence, the nutrient foramen before the birth should be directed horizontally. Many theories have been put forward to account for the direction of foramina and also the anomalously directed ones. Among them the 'periosteal slip' theory of Schwalbe and vascular theory of Hughes are widely accepted in the literature.

It was suggested that the direction of nutrient foramina is determined by the growing end of the bone. The growing end is supposed to grow at least twice as fast as the other end. The nutrient artery runs away from the growing end as the growing bone might pull and rupture the artery. So the nutrient foramina are directed away from the growing end [8].

Bridgeman G et al [11] and Al Motabangi MAH [6] stated that when two nutrient foramina were present, they were not necessarily equal size. In the present study, the size was measured, out of 200 femora 326 foramina obtained 60 (18%) were small, 130 (40%) were medium, and 136 (42%) were of large sized.

Out of 111 femora with double foramina, 90 had different sized foramina, 21 had same sized nutrient foramina, in which 8 had same small size, 7 had same medium size, and 6 had same large size foramina.

6 femora had triple nutrient foramina, 1 had 3 different sized foramina, 3 had 1 small and 2 large sized foramina, and 1 had 2 small sized and 1 medium sized foramina, and 1 had 1 medium and 2 large sized foramina. 1 femur with 4 nutrient foramina had 3 small sized and 1 medium sized foramina.

## CONCLUSION

Studying the nutrient foramina has both morphological and clinical importance. Precise knowledge of nutrient foramen and its variations is mandatory for doctors to predict prognosis of grafts, tumors, fractures of bones and also useful for anthropologist during interpretation of height from a fragment of bone in medicolegal cases and as well as pathological bone

conditions such as developmental abnormalities, fracture healing or acute hematogenic osteomyelitis.

Detailed data on the blood supply to the long bones is invariably crucial in the development of new transplantation and resection techniques in orthopaedics.

Thus the knowledge of nutrient foramina of femur in orthopaedic surgical procedures and in free vascular bone grafting is extremely important and must be preserved in order to promote fracture healing.

**Conflicts of Interests: None**

## REFERENCES

- [1]. Lewis OJ. The blood supply of developing long bones with special reference to the metaphyses. J Bone Joint Surg 1956;38:928-933.
- [2]. Craig JG, Widman D, Van Holsbeeck M. Longitudinal stress fracture: patterns of edema and the importance of the nutrient foramen. Skeletal Radiol 2003;32:22-27.
- [3]. Oyedun O.S. Morphometric study of Diaphyseal nutrient foramen in dried Nigerian femurs: Implications for microvascular bone graft. Advances in life science and technology. 2014;23:91-96.
- [4]. Dr. Ojaswini Malukar, Dr. Hemang Joshi. Diaphyseal Nutrient Foramina in Long Bones and Miniature Long Bones. NJIRM 2011;2(2):23-26.
- [5]. Berard A.; 'Memoire Sur Le Rapport Qui Existe Entre La Direction Des Conduits Nourriciers Des Os Longs Et L'ordre Suivant Lequel Les Epiphyses Se Soudent Au Corps De L'os.' Archives Generales De Medicine, Series 1835;2(7):176-183.
- [6]. Al- Motabagani, M. A. H. The arterial architecture of the human femoral diaphysis. J. Anat. Soc. India 2002;51(1):27-31.
- [7]. Qin Yuepin, Cheng Xinheng, Wu Jinbao, Bai Huiyung. Acta anatomica sinica, 1984;3:239-244.
- [8]. Murlimanju BV, Prashanth KU, Prabhu LV, Chettiar GK, Pai MM, Dhananjaya KV. Morphological and topographical anatomy of nutrient foramina in the lower limb long bones and its clinical importance. The Australasian medical journal. 2011;4(10):530.
- [9]. Peter L. Williams. Gray's Anatomy, Skeletal system. The anatomical basis of medicine and surgery: 38<sup>th</sup> Edition, international edition. Churchill Livingstone; 2000;678-684, 469-471.
- [10]. V. R. Mysorekar. Diaphyseal nutrient foramina in human long bones. J. Anat. 1967;101(4):813-822.
- [11]. G. Bridgeman and M. Brookes. Blood supply to the human femoral diaphysis in youth and senescence. J anat. 1996;188:611-621.
- [12]. Bokariya. P, R. Kothari, J.E. Waghmare, A. M. Tarnekar. Anthropometric study of femur. J MGIMS, September 2009;14(ii):47-49.

- [13]. Murali Krishna S, Udaya Kumar P, Sirisha V , Rajesh V. Morphologic and morphometric study of the nutrient foramina in dry human femur bones of telangana region, *Int J Anat Res* 2016;4(2):2464-68.
- [14]. Pereira G. A. M, Lopes P. T. C, Santos A. M. P. V, and Silveira F. H. S. Nutrient foramina in the upper and lower limb long bones: Morphometric study in bones of Southern Brazilian Adults. *Int. J. Morphol.*, 2011;29(2):514-520.
- [15]. Li Mingyang, Chen Ziwei, Liu Chaobao, Zhu Daoli. The Nutrient Foramen of the Long Bones in Chinese. *Acta Academiae Medicinae Zunyi*, 1980-01-003.
- [16]. F. Forriol Campos, L. Gomez Pellico, M. Gianonatti Alias and R. Fernandez-Valencia. A study of the nutrient foramina in human long bones. *Surg Radiol Anat* 1987;9: 251-255.
- [17]. E. Sendemir and A. Cimen. Nutrient foramina in the shafts of lower limb long bones: Situation and number. *Surg Radiol Anat* 1991;13:105-108.
- [18]. Nurcan Imre, Bilal Battal, Cengiz Han Acikel, Veysel Akyun, Ayhan Comert, Faith Yazar. The demonstration of the number, course, and the location of nutrient artery canals of the femur by multi-detector computed tomography. *Surgical and Radiologic Anatomy*. July 2012;34(5):427-432. *Anat* 1991;13:105-108.
- [19]. Erika Collipal, Ramiro Vargas, Ximena Parra, Hector Silva and Mariano Del Sol. Diaphyseal Nutrient Foramina in the Femur, Tibia and Fibula Bones. *Int J. Morphol.*, 2007;25(2):305-308.

**How to cite this article:**

Raveena Paul GR, Immanuel Navin Kumar Balla, Sreelatha S, Rajasree TK, Krupa Sailaja T. VARIATIONS OF THE NUTRIENT FORAMINA IN DRIED HUMAN FEMUR. *Int J Anat Res* 2019;7(3.1):6780-6785. DOI: 10.16965/ijar.2019.224