

# ILIOPECTINEAL LIGAMENT AS AN IMPORTANT LANDMARK IN ILIOINGUINAL APPROACH OF THE ANTERIOR ACETABULUM: A CADAVERIC MORPHOLOGIC STUDY

Ayman Ahmed Khanfour <sup>\*1</sup>, Ashraf Ahmed Khanfour <sup>2</sup>.

<sup>\*1</sup>Anatomy department Faculty of Medicine, Alexandria University, Egypt.

<sup>2</sup> Chairman of Orthopaedic surgery department Damanhour National Medical Institute Egypt.

## ABSTRACT

**Background:** The iliopectineal ligament is the most stout anterior part of the iliopectineal membrane. It separates "lacuna musculorum" laterally from "lacuna vasorum" medially. This ligament is an important guide in the safe anterior approach to the acetabulum.

**Aim of the work:** To study the detailed anatomy of the iliopectineal ligament demonstrating its importance as a surgical landmark in the anterior approach to the acetabulum.

**Material and methods:** The material of this work included eight adult formalin preserved cadavers. Dissection of the groin was done for each cadaver in supine position with exposure of the inguinal ligament. The iliopectineal ligament and the three surgical windows in the anterior approach to the acetabulum were revealed.


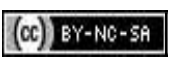
**Results:** Results described the detailed morphological anatomy of the iliopectineal ligament as regard its thickness, attachments and variations in its thickness. The study also revealed important anatomical measurements in relation to the inguinal ligament. The distance between the anterior superior iliac spine (ASIS) to the pubic tubercle ranged from 6.7 to 10.1 cm with a mean value of  $8.31 \pm 1.3$ . The distance between the anterior superior iliac spine (ASIS) to the blending point of the iliopectineal ligament to the inguinal ligament ranged from 1.55 to 1.92 cm with a mean value of  $1.78 \pm 0.15$ .

**Conclusion:** The iliopectineal ligament detailed morphology and attachments are crucial when planning to do anterior approach of the acetabulum to decrease incidence of iatrogenic injury to the femoral vessels.

**KEY WORDS:** Iliopsoas fascia - Iliopectineal membrane - Iliopectineal ligament - Inguinal ligament -Anterior acetabular approach.

**Address for Correspondence:** Ayman Ahmed Khanfour: Assistant professor in the human Anatomy and Embryology department, Faculty of Medicine, University of Alexandria, Egypt.

Mobile: 00201223815866. E-Mail: [aymn222@hotmail.com](mailto:aymn222@hotmail.com)

Access this Article online	Journal Information
<b>Quick Response code</b>  DOI: 10.16965/ijar.2019.274	<b>International Journal of Anatomy and Research</b> ICV for 2016 90.30 ISSN (E) 2321-4287   ISSN (P) 2321-8967 <a href="https://www.ijmhr.org/ijar.htm">https://www.ijmhr.org/ijar.htm</a> DOI-Prefix: <a href="https://dx.doi.org/10.16965/ijar">https://dx.doi.org/10.16965/ijar</a> 
	Article Information
	Received: 17 Jul 2019 Peer Review: 17 Jul 2019 Revised: None
	Accepted: 19 Aug 2019 Published (O): 05 Sep 2019 Published (P): 05 Sep 2019

## INTRODUCTION

The iliopsoas fascia is the mother name given to all the relatively dense layer of fascia that covers the anteromedial aspect of iliopsoas muscle as a whole. It tethers the iliopsoas muscle, femoral nerve and lateral cutaneous nerve of the thigh to the iliac fossa. It could be

considered as a continuation of the transversus abdominis fascia. It is thinner anteriorly but progressively becomes thicker medially [1,2].

The iliopectineal membrane is the relatively denser medial part of this iliopsoas fascia on its anteromedial surface run the great femoral vessels. Consequently, the most anterior part of

this iliopectineal membrane forms an even more stout ligament like structure that is called the iliopectineal ligament which subdivides the space deep to the inguinal ligament into a lateral muscular lacunae and a medial vascular lacunae [3].

Surgical treatment of anterior acetabular fractures entails good anatomic reduction with restoring hip congruency [4,5]. This necessitates adequate anterior exposure using the well-known ilioinguinal approach in which isolation of the iliopectineal ligament is a crucial step [6]. Sharp cutting of this iliopectineal ligament as a crucial step in the ilioinguinal approach to mobilize the iliopsoas muscle to permit good exposure, reduction and fixation of anterior acetabular fractures located anyway from the anterior aspect of the sacroiliac joint up to the pubic symphysis, including exposure of the quadrilateral surface. Unfortunately, great femoral vessels (artery and vein) lie directly on the anteromedial surface of this ligament, putting them at high risk for iatrogenic injury [7,8]. Limited sources about the detailed morphological anatomy about this important iliopectineal membrane and ligament was the major driving force for this study.

**Aim of the work:** The aim of this work was to study the detailed anatomy of the iliopectineal ligament demonstrating its importance as a surgical landmark in the anterior approach to the acetabulum. And using it together with special surgical tactics to prevent iatrogenic injury to great femoral vessels.

## MATERIALS AND METHODS

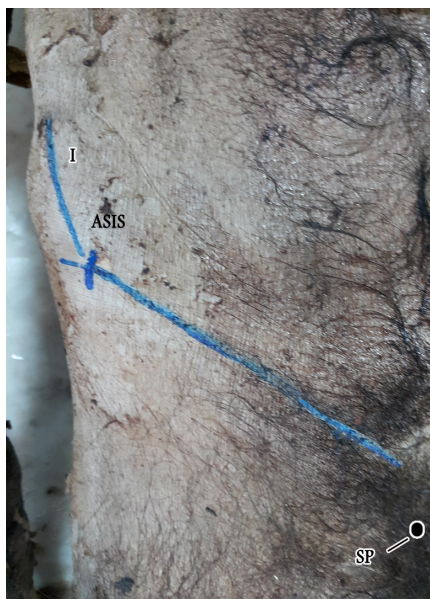
The material of this work included eight adult formalin preserved cadavers obtained from the Dissecting Room of Anatomy Department, Faculty of Medicine, Alexandria University.

In this study, the ilioinguinal approach that was originally described in the literature of Emile Letournel in 1993 was simulated in all of the cases included in this study [7]. The cadaveric position was supine with exposure of the groin area. An incision was done extending along the anterior two-thirds of the iliac crest, passing through the anterior superior iliac spine (ASIS) then continued to the midline, approximately two fingerbreadths above the pubic symphysis

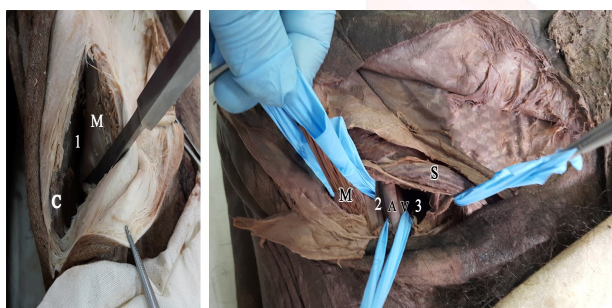
(Fig. 1). The skin and subcutaneous tissues along the proposed line of incision were deepened up to the aponeurosis of the external oblique muscle. At the end, the ilioinguinal approach was completed by developing three anatomical windows (Fig. 2). The 1st window was developed by subperiosteal dissection of the iliac crest and iliac fossa elevating the insertion of the anterior abdominal wall muscles together with the origin of the iliacus in continuity up to the sacroiliac joint posteriorly and the pelvic brim anteriorly. The 2nd window starts by opening the anterior wall of the inguinal canal by incising the external oblique aponeurosis from the anterior superior iliac spine (ASIS) up to the midline 1 cm above the superficial inguinal ring. The spermatic cord or the round ligament was retracted by a rubber sling medially.

Then, the posterior wall of the inguinal canal is opened by sharp incising the inguinal ligament into two equal superior and inferior flaps, exposing the subinguinal region posterior to the inguinal ligament. This region is subdivided into two spaces; the "lacuna vasorum" lies medially and the "lacuna musculorum" laterally separated by the iliopectineal ligament that is the issue of this study. Now the 2nd window can be developed by retracting the "lacuna musculorum" containing the iliopsoas, the femoral nerve and the lateral cutaneous nerve of the thigh laterally, and the "Lacuna vasorum" containing the external iliac vessels medially with the iliopectineal ligament. At this stage, the iliopectineal membrane and ligament become fully isolated and their detailed anatomical morphology was studied as regards their attachment, thickness, point of its hitch hike of the iliopectineal ligament to the inguinal ligament, and their relation to the vital structures especially great femoral vessels. In the original description of this approach, the iliopectineal ligament and membrane were completely incised in an anteroposterior direction up to the pelvic brim in order to freely mobilize the iliopsoas muscle developing the 3rd window by retracting the slung lacuna vasorum laterally and the spermatic cord medially. At this step, a detailed morphological anatomy of the iliopectineal membrane and ligament took place.

**Fig. 1:** A photograph of a right side groin showing the line of incision starting from the anterior two-thirds of the iliac crest (I), passing through the anterior superior iliac spine (ASIS) then continues to the midline, approximately two fingerbreadths above the pubic symphysis (SP).



**Fig. 2:** A photograph of a right groin showing the three windows. The left of the photograph showing the first window (1) while the right part of the photograph showing the second and third windows (2) and (3) respectively. (C: Iliac crest - M: Iliopsoas muscle - A: External iliac artery - V: External iliac vein - S: Spermatic cord).



Anatomical measurements involved measurement of the distance between the anterior superior iliac spine (ASIS) to the pubic tubercle and the distance between the anterior superior iliac spine (ASIS) to the blending point of the iliopectineal ligament to the inguinal ligament. These measurements were done using manual Smith Vernier caliper.

In one specimen, in order to study the morphology of all the investing iliopsoas fascia as a whole, the anterior abdominal wall and all abdominal viscera in front of the ilacus muscle with its fascia were removed.

**Statistical analysis:** The Data was collected and entered into the personal computer. Statistical

analysis was done using Statistical Package for Social Sciences (SPSS/version 20) software.

Arthematic mean, standard deviation were used to the numerical measurements. To find the association between two variables, Spearman correlation coefficient test was used and the level of significant was 0.05.

To predict the distance of the blending point of iliopectineal ligament to inguinal ligament, the multiple logestic regression analysis was done to predict the equation.

## RESULTS

**Morphological findings:** The investing fascia of the iliopsoas was found to invest the iliopsoas muscle together with the femoral nerve and the lateral cutaneous nerve of the thigh. It forms a thin membrane anteriorly, then it becomes thicker as we go medially to form the iliopectineal membrane. Again, the most anterior part of the iliopectineal membrane becomes even thicker forming the iliopectineal ligament (**Fig. 3**). The attachments of the iliopsoas fascia as a whole are: laterally to the iliac crest, medially to the pelvic brim, posteriorly to the sacrum and anteriorly attached to the inguinal ligament.

So, the iliopectineal ligament is the stoutest part of this fascia at all. It runs antero-laterally in an oblique inclination from the “iliopectineal eminence” to hitch hick the inguinal ligament approximately at the region nearly at the junction between its lateral third and medial two thirds. **Fig 4**

## Measurements:

a. Distance between the anterior superior iliac spine (ASIS) to the pubic tubercle. **Fig 5** (Tab. 1)

The distance between the anterior superior iliac spine (ASIS) to the pubic tubercle ranged from 6.7 to 10.1 cm with a mean value of  $8.31 \pm 1.3$

b. Distance between the anterior superior iliac spine (ASIS) to the blending point of the iliopectineal ligament to the inguinal ligament. **Fig 4** (Table 1)

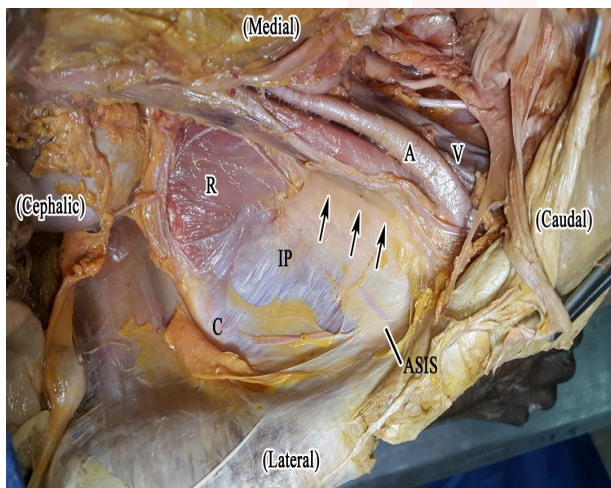
The distance between the anterior superior iliac spine (ASIS) to the blending point of the iliopectineal ligament to the inguinal ligament ranged from 1.55 to 1.92 cm with a mean value of  $1.78 \pm 0.15$



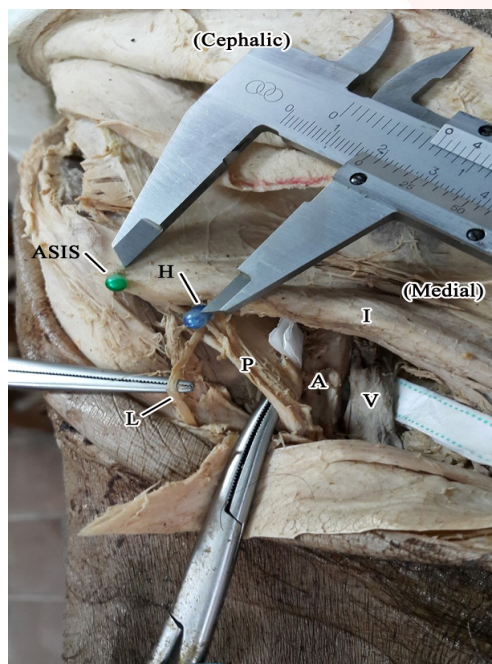
The equation of prediction of the distance between (ASIS) to the blending point of the iliopectineal ligament to the inguinal ligament in relation to the total length of inguinal ligament was:

**Blending point of iliopectineal ligament to inguinal ligament** =  $0.940 + (0.101 \times \text{Inguinal ligament})$  With accuracy = 97.0%.

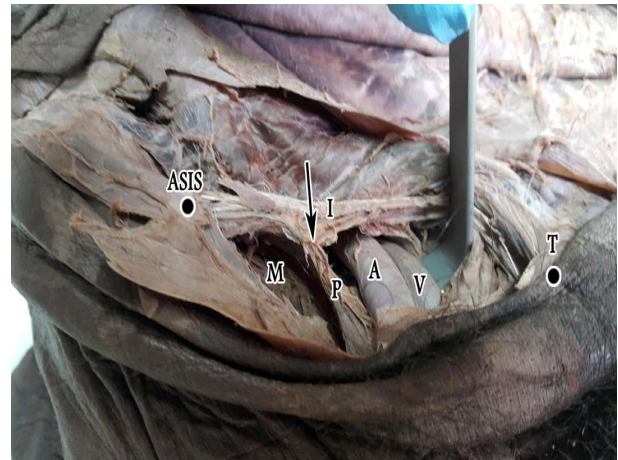
**Fig. 3:** A photograph of a right side cadaver showing the morphology of the iliopsoas fascia after removal of the anterior abdominal wall and viscera. The iliopsoas fascia (IP) seen thin and transparent anteriorly up to the extent that part of it was accidentally removed during dissection (R). It becomes more opaque i.e thicker medially (arrows) forming iliopectineal membrane. (C: Iliac crest – ASIS: Anterior superior iliac spine - A: External iliac artery – V: External iliac vein).



**Fig. 4:** A photograph of a right groin showing the point of hitch hick (H) of iliopectineal ligament (P) to the inguinal ligament (I). (ASIS: Anterior superior iliac spine - A: External iliac artery – V: External iliac vein – L: Lateral cutaneous nerve of thigh)



**Fig. 5:** A photograph of a right groin showing the relation between the length of the inguinal ligament (I) and the blending point (arrow) of the iliopectineal ligament (P) to the inguinal ligament (I). (ASIS: Anterior superior iliac spine - A: External iliac artery – V: External iliac vein – T: Pubic tubercle – M: iliopsoas muscle)



**Table 1:** Correlation between the total length of the inguinal ligament and the distance between (ASIS) to the blending point of the iliopectineal ligament to the inguinal ligament in cm.

	Total length of the inguinal ligament in cm	Distance between (ASIS) to the blending point of the iliopectineal ligament to the inguinal ligament in cm
Range	6.7-10.1	1.55-1.92
Mean	8.31	1.78
S.D.	1.36	0.15
spearman correlation coefficient (r)	0.95	
P value	0.001*	

**Table 2:** Multiple logistic regression analysis to predict the distance between (ASIS) to the blending point of the iliopectineal ligament to the inguinal ligament from the total length of the inguinal ligament.

Model	Sum of Squares	df	Mean Square	F	Sig.
Regression	0.133	1	0.133	55.028	0
Residual	0.014	6	0.002		
Total	0.147	7			

a. Dependent Variable: Distance between (ASIS) to the blending point of the iliopectineal ligament to the inguinal ligament.

Coefficients<sup>a</sup>

Model	Unstandardized Coefficients		Standardized Coefficients	t	Sig.
	B	Std. Error	Beta		
1 (Constant)	0.94	0.115		8.2	0
1 Inguinal ligament	0.101	0.014	0.95	7.418	0

a. Dependent Variable: Distance between (ASIS) to the blending point of the iliopectineal ligament to the inguinal ligament.

## DISCUSSION

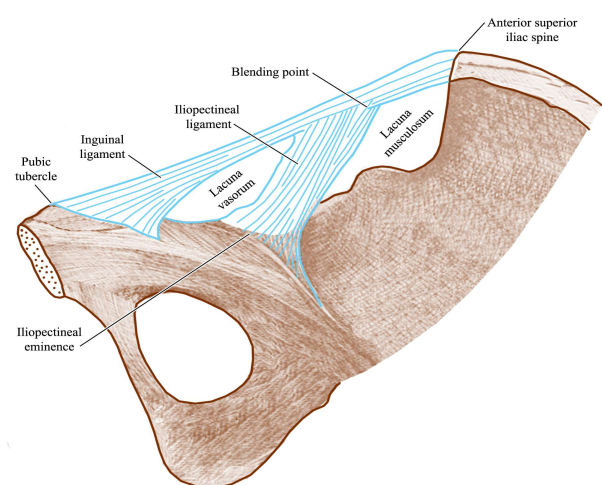
Management of acetabular fractures involving the anterior all and column is challenging [9]. Although nowadays there are many surgical approaches invented to access the anterior acetabular wall and column, still the ilioinguinal approach is considered the state of the art approach for the open surgical reduction and internal fixation of the anterior fractures of the acetabulum [10]. In this approach, dissection around the femoral vessels in its middle window constitutes a high risk for their iatrogenic injury that necessitates special caution [11]. Knowing that these vessels lie directly in a close relation to the anteromedial surface of the iliopectineal membrane and ligament, a detailed study of its morphological anatomy together with carrying out special tacts during surgical dissection can reduce this risk significantly [1,10].

This Ilioinguinal approach was first mentioned by Letournel in 1961 as an extra-pelvic, extra-peritoneal, trans-inguinal canal approach [12,13]. it did not became fully recognized and applied on a wide scale except after publishing this author cadaveric study on that approach in 1993 demonstrating the clear surgical development of the 3 working windows. Unfortunately, he did not pay any attention to describe the surgical anatomic morphology of the iliopectineal ligament, on which this approach is muchly depends on in a clear practical way [7]. Recently, many recent approaches were published, all share the idea of how to avoid dissection in this second dangerous window to avoid iatrogenic injury to femoral great vessels. Of these, Cole JD et al in 1994 described a limited intrapelvic extraperitoneal approach that was called modified Stoppa anterior intrapelvic extra-peritoneal approach [14]. The approach involves a transverse skin incision 2 cm above the pubic symphysis followed by a midline split of the rectus abdominis, with or without iliac crest incision mimicking the first window of the ilioinguinal approach. But still dissection and surgery are carried out beneath and in close relation to the great femoral vessels [14]. Keel M J et al in 2012 described a new anterior intrapelvic, extraperitoneal approach for the surgical management of

displaced anterior acetabular fractures through a longitudinal pararectus incision. Although in their study proved a satisfactory improvement in instrumentation, fracture reduction, and fixation, a potential disadvantage of this approach might be the relatively high risk of entering the peritoneum and vascular injury [9]. Chen K et al in 2018 reported that the single incision used by Keel MJ et al is far cephalad from the anterior bonny pelvis which is the target site for the surgery. They described a similar approach but it was more caudate to the original ilioinguinal approach, that they called “supra-ilioinguinal approach”. They reported easier instrumentation, reduction and fixation of fractures especially that exiting the iliac crest. And low risk for peritoneal injury [15]. So, nowadays there is resurgence again to the ilioinguinal approach [10].

The aforementioned discussion would highlight the necessity of studding in depth the surgical anatomy and morphology of the iliopectineal membrane and ligament as an important landmark for avoiding injury to the great femoral vessels. On reviewing the literature, we did not come through any paper discussing in detail the surgical anatomy and morphology of this ligament.

**Fig. 6:** A diagrammatic representation of inside axio-caudal view of right groin showing the relation between inguinal ligament and the blending point of the iliopectineal ligament. (P) to the inguinal ligament (I). (ASIS: Anterior superior iliac spine - A: External iliac artery - V: External iliac vein - T: Pubic tubercle - M: iliopsoas muscle)



As regards the iliopectineal membrane is the thickened medial part of the investing iliopsoas fascia, it has a bonny origin starts from



the pectineal eminence anteriorly to the pelvic brim posteriorly. Again, The Iliopectineal ligament (known also as iliopectineal band or arch) is the most thickened anterior part of this iliopectineal membrane. This band takes origin from the pectineal eminence and hitch hick the inguinal ligament at a point ranging from 1.55 to 1.92 cm from the (ASIS) with a mean value of  $1.78 \pm 0.15$  (**Fig. 6 Diagram**). It separates the subinguinal space into the corpus musculosum from the corpus vasculosum. this was also demonstrated by Wang P et. al in 2016 [11].

This was found to be useful for the orthopaedic surgeon practicing the ilioinguinal approach to the anterior acetabulum. Where it is advisable to the surgeon to **start** the step of incising the inguinal ligament in order to reach the parietal pelvis on the most lateral part near to the ASIS and then go by the incision medially until reaching the hitch hick point of the iliopectineal ligament to it. At that point, to continue safe dissection as regards the femoral vessels, the surgeon is advised to slip his finger in the cleavage space between the iliopsoas muscle laterally and the **posterolateral aspect** of the iliopectineal ligament medially, this ligament now acts now as an important anatomical and surgical landmark at this stage as the femoral vessels are directly located over its **anteromedial surface**. On doing so, the femoral vessels are now clearly located and safely slung by a soft rubber band and retracted medially before completing the development of the 2nd window by incising this ligament in an **anteroposterior** direction to enable the surgeon completing his approach to bonny pelvis by mobilizing this iliopsoas membrane.

Another important value of the iliopectineal ligament arose during the surgical treatment of developmental dislocation of the hip, where the paediatric orthopaedic surgeons during practising open reduction for congenital dislocation of the hip, mobilization of the iliopsoas muscle by internal rotating it on itself at the pelvic prim to release its underneath contracted tendon is an important step. In this step, the iliopectineal ligaments stands as a safeguard against reaching the femoral vessels and preventing their iatrogenic injury. These facts were supported also by Glorion, C. et al (16, 17) ,

Weinstein, S. L. et al [18] and Yorgancigil, H. el al [19].

## CONCLUSION

Iliopectineal ligament is an important surgical anatomical landmark for orthopaedic surgeons practicing acetabular or hip surgery through ilioinguinal anterior pelvic approach. This is because it is a very tough ligament that acts as both landmark and safeguard protecting the femoral vessels 'that lie directly on its anteromedial surface' during extrapelvic, extraperitoneal dissection to the bony pelvis and acetabulum. Good isolation of this ligament both antromedial and posterolateral surfaces is mandatory to enable isolation and protection of these vessels before its cutting under clear vision.

## ABBREVIATIONS

**ASIS:** Anterior Superior Iliac Spine

**Conflicts of Interests:** None

## REFERENCES

- [1]. Teague DC. Inguinal anatomy and retropubicvascular hazards of the ilioinguinal approach. *Operative Techniques in Orthopaedics*. 1997;7(3):175-83.
- [2]. Basinger H, Hogg JP. *Anatomy, Abdomen and Pelvis, Femoral Triangle*. StatPearls. Treasure Island (FL): StatPearls Publishing StatPearls Publishing LLC.; 2019.
- [3]. Lew V, Kang M. *Anatomy, Pelvis, Femoral Sheath*. StatPearls. Treasure Island (FL): StatPearls Publishing StatPearls Publishing LLC.; 2018.
- [4]. Gansslen A, Grechenig ST, Nerlich M, Muller M, Grechenig W. Standard Approaches to the Acetabulum Part 2: Ilioinguinal Approach. *Acta chirurgiae orthopaedicae et traumatologiae Cechoslovaca*. 2016;83(4):217-22.
- [5]. Akgul T, Coskun O, Korkmaz M, Gurses IA, Sen C, Gayretli O. A Minimally Invasive Technique Using a Modified Stoppa Approach for Periacetabular Osteotomy: A Preliminary Cadaveric Study. *Indian journal of orthopaedics*. 2017;51(6):687-91.
- [6]. Abo-Elsoud M, Radwan YA, Gobba M, Sadek F. Short-segment fixation through a limited ilioinguinal approach for treating anterior acetabular fractures: a historical-control study. *International orthopaedics*. 2014;38(7):1469-75.
- [7]. Letournel E. The treatment of acetabular fractures through the ilioinguinal approach. *Clinical orthopaedics and related research*. 1993(292):62-76.
- [8]. Wang XJ, Lu L, Zhang ZH, Su YX, Guo XS, Wei XC, et al. Ilioinguinal approach versus Stoppa approach for open reduction and internal fixation in the treatment of displaced acetabular fractures: A systematic review and meta-analysis. *Chinese journal of*

- traumatology = Zhonghua chuang shang za zhi. 2017;20(4):229-34.
- [9]. Keel MJ, Ecker TM, Cullmann JL, Bergmann M, Bonel HM, Buchler L, et al. The Pararectus approach for anterior intrapelvic management of acetabular fractures: an anatomical study and clinical evaluation. The Journal of bone and joint surgery British volume. 2012;94(3):405-11.
- [10]. Tosounidis TH, Giannoudis VP, Kanakaris NK, Giannoudis PV. The Ilioinguinal Approach: State of the Art. JBJS essential surgical techniques. 2018;8(2):e19.
- [11]. Wang P, Zhu X, Xu P, Zhang Y, Wang L, Liu X, et al. Modified ilioinguinal approach in combined surgical exposures for displaced acetabular fractures involving two columns. SpringerPlus. 2016;5(1):1602.
- [12]. Letournel E. Fractures of the acetabulum. A study of a series of 75 cases. 1961. Clinical orthopaedics and related research. 1994(305):5-9.
- [13]. Judet R, Judet J, Letournel E. Fractures of the acetabulum: classification and surgical approaches for open reduction. Preliminary report. The Journal of bone and joint surgery American volume. 1964;46:1615-46.
- [14]. Cole JD, Bolhofner BR. Acetabular fracture fixation via a modified Stoppa limited intrapelvic approach. Description of operative technique and preliminary treatment results. Clinical orthopaedics and related research. 1994(305):112-23.
- [15]. Chen K, Ji Y, Huang Z, Navinduth R, Yang F, Sun T, et al. Single Modified Ilioinguinal Approach for the Treatment of Acetabular Fractures Involving Both Columns. Journal of orthopaedic trauma. 2018;32(11):e428-e34.
- [16]. Glorion C. Surgical reduction of congenital hip dislocation. Orthopaedics & traumatology, surgery & research : OTSR. 2018;104(1s):S147-s57.
- [17]. Thawrani D, Sucato DJ, Podeszwa DA, DeLaRocha A. Complications associated with the Bernese periacetabular osteotomy for hip dysplasia in adolescents. The Journal of bone and joint surgery American volume. 2010;92(8):1707-14.
- [18]. Weinstein SL, Dolan LA, Morcuende JA. The 2018 Nicholas Andry Award: The Evidence Base for the Treatment of Developmental Dysplasia of the Hip: The Iowa Contribution. Clinical orthopaedics and related research. 2018;476(5):1043-51.
- [19]. Yorgancigil H, Aslan A. Comparison of the clinical and radiological outcomes of open reduction via medial and anterior approach in developmental dysplasia of the hip. Eklem hastaliklari ve cerrahisi = Joint diseases & related surgery. 2016;27(2):74-80.

#### How to cite this article:

Ayman Ahmed Khanfour, Ashraf Ahmed Khanfour. ILIOPECTINEAL LIGAMENT AS AN IMPORTANT LANDMARK IN ILIOINGUINAL APPROACH OF THE ANTERIOR ACETABULUM: A CADAVERIC MORPHOLOGIC STUDY. Int J Anat Res 2019;7(3.3):6976-6982. DOI: 10.16965/ijar.2019.274