

# A VOLUMETRIC STUDY OF HIPPOCAMPUS IN CADAVERIC HUMAN BRAINS

Maitreyee M.Kulkarni <sup>1</sup>, Jagdish S.Soni <sup>\*2</sup>, Shital Bhishma Hathila <sup>3</sup>.

<sup>1</sup> Maitreyee M Kulkarni M.Sc Medical Anatomy, Medical College Baroda, Gujarat, India.

<sup>\*2</sup> Dr.Jagdish S.Soni, M.S.Anatomy, Associate Professor, Anatomy Department, Medical College, Baroda, Gujarat, India.

<sup>3</sup> Assistant Professor, Anatomy Department, Medical College, Baroda, Gujarat, India.

## ABSTRACT

**Background:** Hippocampus is one of the key parts of limbic system. It is located in the floor of the inferior horn of lateral ventricle.



**Materials and methods:** The study is conducted on 50 Hippocampi removed from 25 cadaveric brains in Medical College Baroda, Gujarat. The volume of each is measured by water displacement method.

**Results:** It is observed that the mean volume for the sample is  $2.26 \pm 0.88$ cc. The mean volume on right side is  $2.37 \pm 0.88$ cc and on the left side is  $2.12 \pm 0.88$ cc. The mean volumes seen in male and female hippocampi are  $2.14 \pm 0.70$ cc and  $2.52 \pm 1.21$ cc respectively. The mean volume in the age group 60-80 years is  $2.55 \pm 0.65$ cc and in the age group 81 years onwards, it is  $2.0 \pm 1.03$ cc. The difference in volumes of the two age groups is found to be statistically significant.

**Conclusion:** The study will be useful to anatomists, Neurologists, Neurosurgeons and psychiatrists alike.

**KEY WORDS:** Hippocampus, limbic system, Volume, age.

**Corresponding Author:** Dr.Jagdish S.Soni, P-13, Aviral Society, Opposite Mangalam Duplex, Sama-Savli Road, Baroda, Gujarat-390024 Mobile:09426587464 E-Mail: [ashushiti@yahoo.co.in](mailto:ashushiti@yahoo.co.in)

Access this Article online	Journal Information
<b>Quick Response code</b>  DOI: 10.16965/ijar.2019.285	<b>International Journal of Anatomy and Research</b> ICV for 2016 90.30 ISSN (E) 2321-4287   ISSN (P) 2321-8967 <a href="https://www.ijmhr.org/ijar.htm">https://www.ijmhr.org/ijar.htm</a> DOI-Prefix: <a href="https://dx.doi.org/10.16965/ijar">https://dx.doi.org/10.16965/ijar</a> 
	Article Information
	Received: 28 Jul 2019 Peer Review: 28 Jul 2019 Revised: None
	Accepted: 12 Sep 2019 Published (O): 05 Oct 2019 Published (P): 05 Oct 2019

## INTRODUCTION

Famous Psychologist Michael Gazzaniga once stated that the human brain is generally regarded as a complex web of adaptations built into nervous system, even though no one knows how. Hippocampus is a small component of this labyrinthine anatomy of brain and is a part of limbic system. In 1878 Broca first coined the term "Limbic system" as the structure resembled a ring of gray matter on medial aspect of each hemisphere and comprised of subcallosal, cingulate gyrus, parahippocampal gyrus and hippocampal formation [1].

Hippocampal formation is further said to have

Hippocampus (Ammon's horn or the 'cornua ammonis'), the dentate gyrus, subicular complex (subiculum, presubiculum, parasubiculum) and the entorhinal cortex (area 28) [2]. The hippocampus is C shaped in coronal section and lies along the floor of the inferior horn of the lateral ventricle [1]. It is further subdivided into three parts with head placed rostromedially, Body seen sagittally and a tail running caudal and dorsal [3]. The anterior end is broad, and is referred as the pes hippocampi due to paw like resemblance. It generally bears two or three shallow grooves [2]. Hippocampus plays a significant role in spatial and episodic

memory which is recalled by a voluntary effect [4]. Pathological changes affect the structure and function of hippocampus in various conditions such as amnesia [3], mesial temporal sclerosis, Alzheimer's disease, Schizophrenia [5] and infections such as herpes simplex encephalitis [4]. With the advent of technology Magnetic Resonance Imaging is becoming the most important diagnostic tool in studying such changes in hippocampus [4]. Removal of hippocampus or hippocampectomy is considered to be a leading solution in the treatment of intractable seizures [3]. Therefore both the diagnosis and surgical treatments need a solid anatomical foundation which renders a study like this extremely useful.

## MATERIALS AND METHODS

The present study was conducted after taking permission from the Institutional Ethical Committee for Human Research (IECHR) of Medical College Baroda, Gujarat. 50 Hippocampi were isolated from 25 brains from the cadavers donated to the Anatomy department. Hippocampi were dissected by separating the two parts of cerebral hemisphere and approaching the floor of the lateral ventricle contained in part of cerebral hemisphere with temporal and occipital lobes [14, Figure1]. The volume of the hippocampus was measured by water displacement method with the help of  $\pi r^2 h$  [3]. Data is analyzed statistically using student's t- test. p values < 0.05 are considered significant. Data is presented as mean  $\pm$  SD and analyzed with the help Microsoft Excel.

## OBSERVATIONS & RESULTS

The 50 hippocampi were further subdivided into 25 of each right and left sides. The sample comprised of 36 hippocampi from male brains and 18 from female brains. They were also analyzed in terms of two age groups; the first group comprising of ages 60 to 80 years and the second from 81 years onwards.

The mean volume for the sample is observed as  $2.26 \pm 0.88$ cc. The mean volume on right side is  $2.37 \pm 0.88$ cc and on the left side is  $2.12 \pm 0.88$ cc. The mean volume seen in male and female hippocampi are  $2.14 \pm 0.70$ cc and  $2.52 \pm 1.21$ cc respectively. The mean volume in the age group 60-80 years is  $2.55 \pm 0.65$ cc and in the age group

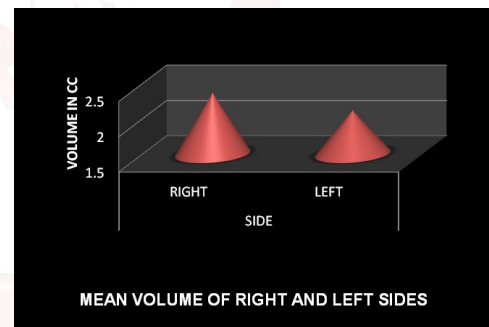
81 years onwards, it is  $2.0 \pm 1.03$ cc [table1, Graph 1, Graph 2, Graph 3 ].

It is observed that the mean volume of a right sided hippocampus is slightly larger than the left sided one. It is also seen that females tend to have slightly more voluminous hippocampus. Though both the results were found to be statistically insignificant as the  $p < 0.05$ . However, the difference in the volumes in the age groups 60-80years and 81 years onwards is found to be statistically significant as the p value is 0.02 at CI 95% [table1][Graph 3].

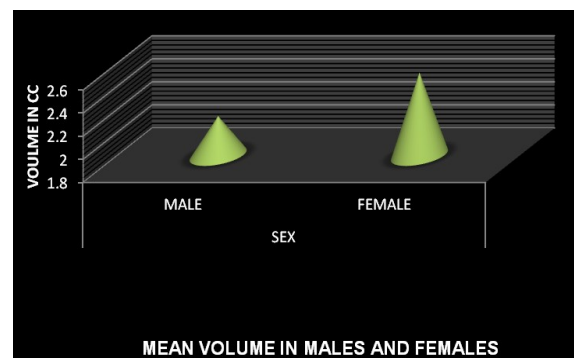
**Table 1:** Mean Volumes of Hippocampus According To Different Parameters.

Volume in cc	Right	Left	Male	Female	Age 60-80 years	Age 81 years
Mean	2.37	2.12	2.14	2.52	2.55	2
SD	0.88	0.88	0.7	1.21	0.65	1.03
t value	1.04		1.35		2.25	
p	0.32		0.18		0.02	

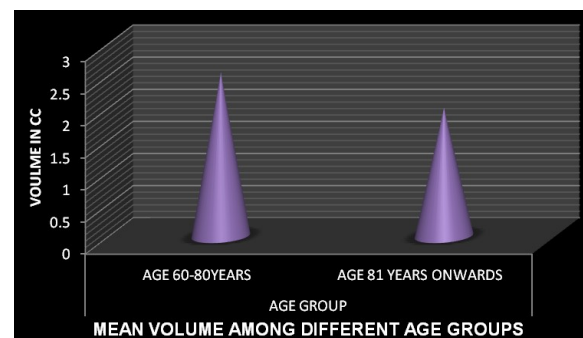
**Graph 1:** Comparison of volume on right and left sides.



**Graph 2:** Comparison of volume in males and females.

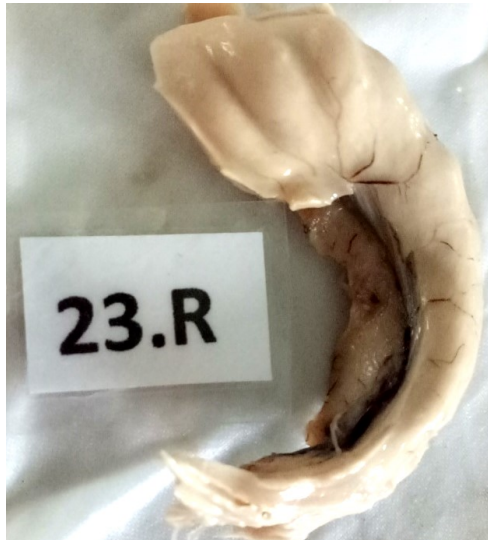


**Graph 3:** Comparison of volume of different age groups.



**Table 2:** Comparison of the Data In Present Study With Other Studies.

Author	Volume of right Hippocampus (in cc)	Volume of left Hippocampus (in cc)	Volume among males (in cc)	Volume among female (in cc)	Volume in age group 60-80 years	Volume in age group 81 years onwards
Present study	2.37±0.88	2.12±0.88	2.14±0.70	2.52±1.21	2.55±0.65	2.0±1.03
B.Narsinga Rao et al 2012 [7]	11.83	11.71	Not measured	Not measured	Not measured	Not measured
Yucel et al 2002 [8]	3.80±0.40	3.69±0.38	3.802±0.397	3.805±0.420	Not measured	Not measured
Watson et al 1992 [9]	5.26±0.65	4.903±0.68	Not measured	Not measured	Not measured	Not measured

**Fig. 1:** Hippocampus dissected from cadaveric brain.


## DISCUSSION

The present study directly studies the volume of hippocampus as an independent entity in contrast to most of the authors except B. Narasinga Rao et al [7]. B.Narsinga Rao et al attributes diverse the results among different authors to variable criteria of MRI machines in evaluating the limits of the tissue or the organ involved [7]. The observations in the current study can be compared with studies that of B.Narsinga et al [7], Yucel et al [8] Watson et al [9], Gonzalez et al[10] and others as follows [table 2]:

The Mean volume of the hippocampi observed on the right and left sides is similar to that of Yucel et al [8] and Watson et al [9]. Yucel et al reports the volumes to be 3.80±0.40cc & 3.69±0.38cc on right & left sides respectively [8]. Watson et al noted the volumes to be 5.26±0.65cc on right side & 4.90±0.68cc on left side [9].[table2]

The results of the current study however differ considerably with that of B. Narasinga Rao et al who observe the volume on right and left sides to be 11.83cc and 11.71cc respectively. The mean age of the sample in the current study is

83 years whereas in B.Narsinga rao et al it is 56.46 years [7, table2].

Gonzalez et al observe the Hippocampal volumes being 3.15±1.03cc & 2.30±0.79 cc on right and left sides in age groups below 65years and in age group above 65 years it is observed to be 2.72±0.74 cc and 2.92±1.61cc on right and left sides respectively [10].

Simic et al reports the Mean volume of hippocampus in sample with mean age 80 years to be 1.39±0.17cc [11].

## CONCLUSION

The hippocampus exhibits plasticity in structure all throughout the life and therefore based on the older incidences faced by the organism, changes constantly [12]. It is thus significant to study the volumetric changes in its structure as it will be helpful in advancement of research in neuroscience specially pertaining to diseases like Alzheimer's, Schizophrenia and mesial temporal sclerosis[5].

## ABBREVIATIONS

**Cc** - cubic centimeters

**CI** - Confidence Interval

**R** - RIGHT

**Conflicts of Interests:** None

## REFERENCES

1. Barrs's The Human Nervous System: An Anatomical Viewpoint by John Kiernan and Raj Rajakumar in chapter 18, 10<sup>th</sup> edition; Pg 323-38.
2. Gray's Anatomy The Anatomical basis of Clinical Practice by Susan Standring in chapter 23, 40<sup>th</sup> edition; Pg 335-60.
3. C.Destrieux, D.Bourry, S.Velut Surgical Anatomy of Hippocampus. Neurochirurgie 2013;59:149-158.
4. Sven Dekeyzer & Isabelle De Kock & Omid Nikoubashman, Stephanie Vanden Bossche & Ruth Van Eetvelde & Jeroen De Groote & Marjan Acou & Martin Wiesmann & Karel Deblaere & Eric Achten B; Unforgettable – a pictorial essay on anatomy and pathology of the hippocampus. Insights Imaging 2017;8:199–212.

- [5]. Rajmohan V, Mohandas E. The limbic system. Indian Journal of Psychiatry 2007;49(2):132- 139.
- [6]. Grant's Dissector by Patrick. W. Tank; Lippincott Williams & Wilkins, 15<sup>th</sup> Edition;306-308.
- [7]. Rao B, Prasad Rao K, Rao R. Morphometric Study Of Hippocampus In Adult Human Brains. International Journal of basic and applied Basic sciences,2012;2(2):139-143.
- [8]. Yucel K, Hakyemez B, Parlak M Morphometry of some elements of limbic system in normal population: a quantitative MRI study. Neuroanatomy, 2002;1:15-21.
- [9]. C. Watson, MD, PhD; F. Andermann, MD, FRCP(C); P. Gloor, MD, PhD; M. Jones-Gotman, PhD; T. Peters, PhD; A. Evans, PhD; A. Olivier, MD, PhD, FRCS(C); D. Melanson, MD; and G. Leroux, RT Anatomic basis of amygdaloid and hippocampal volume measurement by magnetic resonance imaging; NEUROLOGY 1992;42: 1743-1750.
- [10]. Delgado-González JC, Mansilla-Legorburo F, Florensa Vila J, Insausti A M, Viñuela A, Tuñón Álvarez T, et al. Quantitative Measurements in the Human Hippocampus and Related Areas: Correspondence between Ex-Vivo MRI and Histological Preparations. PLoS ONE 2015;10(6): e0130314. doi:10.1371/journal.pone.0130314
- [11]. Goran Simic, Ivica Kostovic, Bengt Winblad, And Nenad Bogdanovic Volume And Number Of Neurons Of The Human Hippocampal Formation In Normal Aging And Alzheimer's Disease. The Journal Of Comparative Neurology 1997;379:482–494.
- [12]. K. R. S. Prasad Rao. CYTOARCHITECTURE OF HUMAN ADULT HIPPOCAMPUS. Int J Anat Res 2016;4(3):2764-2770. DOI: 10.16965/ijar.2016.330.

**How to cite this article:**

Maitreyee M.Kulkarni, Jagdish S.Soni, Shital Bhishma Hathila. A VOLUMETRIC STUDY OF HIPPOCAMPUS IN CADAVERIC HUMAN BRAINS. Int J Anat Res 2019;7(4.1):7003-7006. DOI: 10.16965/ijar.2019.285