

STUDY ON THE INCIDENCE OF OCCURRENCE OF THE OSSIFICATION OF SUPERIOR TRANSVERSE SCAPULAR LIGAMENT WITH ITS CLINICAL IMPLICATIONS

Panjala Ashok *¹, Shiny Vinila B H ².

*¹ Assistant Professor, Department of Anatomy, Deccan College of Medical Sciences, Hyderabad. Telangana, India

² Senior Lecturer, Department of Anatomy, Panineeya Mahavidyalaya Institute of Dental Sciences, Hyderabad, Telangana, India

ABSTRACT

Introduction: Supra scapular notch is present on the superior border of the scapula. It gives passage to the suprascapular nerve. The supra scapular notch is bridged by the superior transverse scapular ligament and converted into supra scapular foramen. Ossification of this superior transverse scapular ligament may compress or entrap the suprascapular nerve which is passing through the foramen. The present study was undertaken to find out the incidence of occurrence of the ossification of superior transverse scapular ligament.

Materials and methods: 89 scapulae were collected from the Department of Anatomy, Deccan College of Medical Sciences, Hyderabad. Damaged scapulae were excluded. All the scapulae were examined to note the incidence of occurrence of the ossification of the transverse scapular ligament and also any variations of it.

Results: 15 scapulae were bearing ossified superior transverse scapular ligament in which 6 were of the right side and 6 were of the left side. Duplication of the superior transverse scapular ligament was observed in one left scapula. Incomplete ossification was observed in 2 scapulae 1 on the right and another on the left side.

Conclusion: Based on the results of the present study, ossification of the transverse scapular ligament is not very rare in this populations group. So, the knowledge about the ossification of superior transverse scapular ligament and the risk of supra scapular nerve entrapment is very much essential for the physicians and the surgeons while dealing with these cases.

KEY WORDS: Scapula, Ossification, Superior transverse scapular ligament, Nerve entrapment.

Corresponding Author: Dr P Ashok, Assistant Professor, Department of Anatomy, Deccan College of Medical Sciences, DMRL X Road, Santosh nagar, Kanchan Bagh, Hyderabad, Telangana, India. Pin: 500058 Contact number: +919849078833. **E-Mail:** drashokpanjala123@gmail.com

Access this Article online	Journal Information
Quick Response code  DOI: 10.16965/ijar.2019.306	International Journal of Anatomy and Research ICV for 2016 90.30 ISSN (E) 2321-4287 ISSN (P) 2321-8967 https://www.ijmhr.org/ijar.htm DOI-Prefix: https://dx.doi.org/10.16965/ijar 
	Article Information
	Received: 30 Aug 2019 Peer Review: 30 Aug 2019 Revised: None
	Accepted: 09 Oct 2019 Published (O): 05 Nov 2019 Published (P): 05 Nov 2019

INTRODUCTION

Scapula is a triangular shaped flat bone which is present at the postero-lateral aspect of the thoracic wall extending from the second rib to seventh rib. It has three borders – superior, medial and lateral. The superior border extends

between the superior and lateral angles. A notch is located at the superior border, near the root of coracoid process called supra scapular notch. A strong fibrous band called as suprascapular ligament converts the notch into foramen by bridging the supra scapular notch. The supra

scapular foramen gives passage to the suprascapular nerve which supplies to the supraspinatus & infraspinatus muscles. The suprascapular vessels pass above the suprascapular ligament. Occasionally this ligament is ossified [1].

The suprascapular ligament is also called as superior transverse scapular ligament. Many variations were reported related to this ligament like calcification or ossification, multiple bands, bifurcation, trifurcation, and hypertrophy [2-5]. Ossification of the superior transverse scapular ligament was considered as anomaly [6]. The variations of the superior transverse scapular ligament and the variations of the size and the shape of the suprascapular notch are the known predisposing factors of suprascapular nerve entrapment followed by neuropathy [7,8]. To treat this neuropathy, the decompression of the suprascapular notch is essential. The ossified superior transverse scapular ligament may cause difficulty while performing the decompression. The proper knowledge about the ossification of superior transverse scapular ligament and its variations is essential for the physicians and surgeons who deal with the entrapment neuropathies of this region.⁵ The present study was undertaken to find out the incidence of occurrence of ossification of the superior transverse scapular ligament in Telangana population.

MATERIALS AND METHODS

The present study was carried out on 89 scapulae in which 45 were belonging to the right side and 44 to the left side. All the scapulae were collected from the Department of Anatomy, Deccan College of Medical Sciences, Hyderabad. Damaged scapulae were excluded from the study and only the fully intact scapulae were included. All the scapulae were numbered and the side determination was done. All the scapulae were observed for any variations and the incidence of the ossification of the superior transverse scapular ligament. The scapulae with ossified superior transverse scapular ligament were separated and the side wise incidence was recorded and photographed. Scapulae with duplication of superior transverse scapular ligament and the incidence of the complete and incomplete ossification of superior transverse scapular ligament were also recorded.

RESULTS

Fig. 1: Pie chart showing the incidence of occurrence of ossification of transverse scapular ligament.

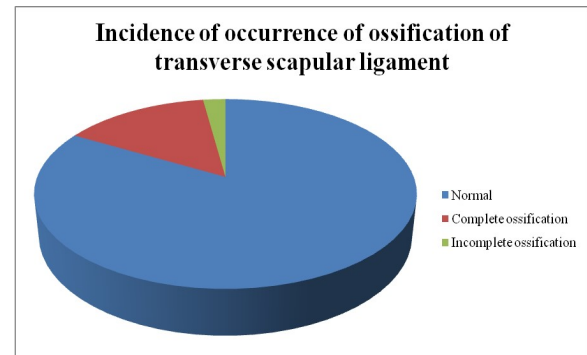


Fig. 2: Showing the complete ossification of transverse scapular ligament on right side.



Fig. 3: Showing the complete ossification of transverse scapular ligament on left side.

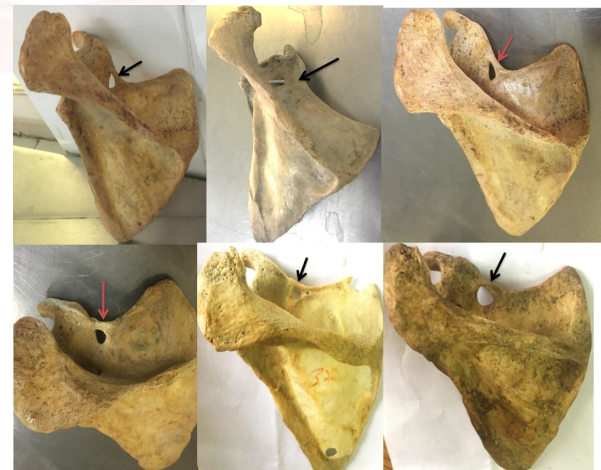
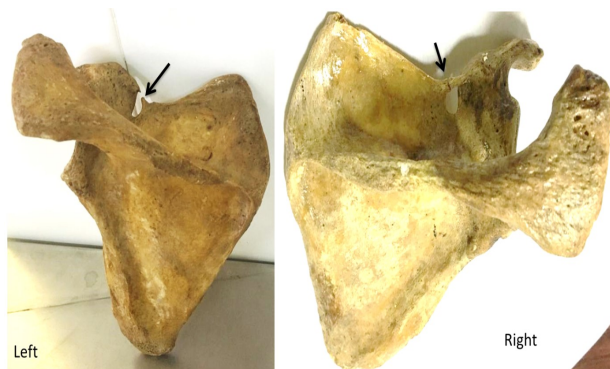


Fig. 4: Showing the duplication of superior transverse scapular ligament on the left scapula.



Fig. 5: Showing the incomplete ossification of superior transverse scapular ligament on the left and right sides.



All 89 scapulae were observed for any variations in the superior transverse scapular ligament. 15 (16.85%) scapulae showed ossification of transverse scapular ligament. Complete ossification of superior transverse scapular ligament was observed in 13 (14.60%) scapulae and incomplete ossification was observed in 2 scapulae (Figure 1). The complete ossification was observed in 6 (6.74%) right scapulae (Figure 2) and in 6 (6.74%) left scapulae (Figure 3) and duplication of superior transverse scapular ligament was observed in 1 (1.12%) left side scapula (Figure 4). Incomplete ossification of superior transverse scapular ligament was observed in 2 scapulae, 1 on the right side and 1 on the left side (Figure 5).

DISCUSSION

The suprascapular nerve entrapment syndrome was first described by André Thomas [9]. The suprascapular nerve entrapment is clinically manifested by the presence of deep, dull and diffuse pain in the postero-lateral aspects of the shoulder, difficulty in the abduction and lateral rotation of the shoulder joint along with the progressive muscular atrophy of the supraspinatus and infraspinatus muscles [10,11].

The suprascapular nerve supplies the supraspinatus and infraspinatus muscles but it does not supply the adjoining skin which leads to the atrophy of the muscles before the onset of deep pain [12]. Knowledge on the ossification and variations of the superior transverse scapular ligament and the mechanism of injury to nerve may be of at most use while planning the treatment of it.

The incidence of occurrence of ossification of superior transverse scapular ligament in the

present study was 16.85% and complete ossification was observed in 14.6% scapulae. The incidence of incomplete or partial ossification of superior transverse ligament was observed in 2.24% scapulae. The incidence of the ossification of superior transverse scapular ligament was much higher when compared with other studies by Kalpana Thounaojam, Suman et al., Rajeev R Desai et al., and Ashok Kumar Singh et al., where they had found it as 2%, 6.1%, 9.7% and 13.33% respectively [13-16]. In Brazilian population the incidence was reported as 30.76% which was much higher than the incidence of the present study [17].

In the present study, duplication of the suprascapula was observed in only 1 scapula out of 89 scapulae. So, the incidence was reported as 1.12%. The ossification of the bifid superior transverse scapular ligament may result in the formation of double suprascapular foramen. Duplication of suprascapular foramen is very rare and also reported by Hrdlika et al., in Caucasian male, Wang et al., in Chinese and Polguj et al., in Polish population [18-20]. Four possible mechanisms of formation of the duplication of the superior transverse scapular ligament were explained by previous authors. The first possibility is due to ossification of the superior transverse scapular ligament and the anterior coracoscaphic ligament. The second possibility is the ossification of bifid superior transverse scapular ligament. The third possibility is the partial ossification of trifid superior transverse scapular ligament and the ossification of superior and inferior bands of the trifid superior transverse scapular ligament. The fourth possibility is the ossification of the bifid anterior coracoscaphic ligament.^{4,20} In the present study, the duplication of the suprascapular foramen may be because of the ossification of bifid superior transverse scapular ligament.

CONCLUSION

The incidence of occurrence of the ossification of the superior transverse scapular ligament was 16.8% in Telangana population. It indicates that, it is not a rare entity. The knowledge on the variations and the ossification of the superior transverse scapular ligament is very much essential for the orthopaedic surgeons and

neurosurgeons while treating shoulder pain and also while performing arthroscopic shoulder procedures.

Conflicts of Interests: None

REFERENCES

- [1]. Standring S, Pectoral girdle and upper limb in Gray's Anatomy: The Anatomical Basis of Clinical Practices, Johnson D & Collins P. , Eds. Churchill Livingstone, New York, USA, 40th ed, 2008; 793-821.
- [2]. Cohen, S. B.; Dnes, D.M. & Moorman, C.T. Familial calcification of the superior transverse scapula ligament causing neuropathy. Clin. Orthop. Rel. Res. 1997; 334:131-35.
- [3]. Khan, M. A. Complete ossification of the superior transverse scapular ligament in an Indian male adult. Int. J. Morphol. 2006; 24(2):195-6.
- [4]. Praisy Joy, Manisha B. Sinha, Bikash Chandra Satapathy. The Ossified Bifid Superior Transverse Scapular Ligament Causing a Double Suprascapular Foramen: A Case Report. Journal of Clinical and Diagnostic Research. 2015; 9(6): AD03-AD04.
- [5]. Ticker J. B.; Djurasovic M.; Strauch R. J.; April, E.W.; Pollock, R. G.; Flatow, E. L. & Bigliani, L.U. The incidence of ganglion cysts and variations in anatomy along the course of the suprascapular nerve. J. Shoulder Elbow Surg. 1998; 7(5):472-478.
- [6]. Harris RI, Vu DH, Sonnabend DH, Goldberg J A, Walsh WR. 2001. Anatomic variance of the coracoclavicular ligaments. J. Shoulder Elbow Surg. 10:585-8
- [7]. Dunkelgrun M, Iesaka K, Park SS, Kummer FJ, Zuckerman JD. 2003. Interobserver reliability and intraobserver reproducibility in suprascapular notch typing. Bull Hosp Joint Dis. 61:118-22.
- [8]. Rengachary SS, Burr D, Lucas S, Hassanein KM, Mohn MP, Matzke H. 1979. Suprascapular entrapment neuropathy: a clinical, anatomical, and comparative study. Part 2. Anatomical study. Neurosurg. 5:447-51.
- [9]. M. Pe'cina, C. A. Cummins, T. M. Messer, and G. W. Nuber, "Who really first described and explained the suprascapular nerve entrapment syndrome?" Journal of Bone and Joint Surgery. 2001; 83(8): 1273–1274.
- [10]. J. Gosk, M. Urban, and R. Rutowski, "Entrapment of the suprascapular nerve: anatomy, etiology, diagnosis, treatment" Ortopedia Traumatologia Rehabilitacja. 2007; 9(1): 68–74.
- [11]. H Zehetgruber, H Noske, T Lang, and C Wurnig. "Suprascapular nerve entrapment. A meta-analysis," International Orthopaedics. 2002; 26 (6): 339–343.
- [12]. Thompson W, Kopell H. Peripheral entrapment neuropathies of the upper extremity. N Engl J Med 1959; 260: 1261-1265.
- [13]. Kalpana Thounaojam, Renuca Karam, N. Saratchandra Singh. Ossification of transverse scapular ligament. Journal of Evolution of Medical and Dental Sciences. 2013; 2(12):1790-1791.
- [14]. Suman P, Mahato R, Sabita Singh, Arun Kumar, Bilodi S. Complete ossification of superior transverse scapular ligament: incidence and its clinical implications. Int J Cur Res Rev. 2013; 5 (13): 80-87.
- [15]. Rajeev R Desai, Manoj P Ambali, and Medha A Doshi. Incidence of ossification of superior transverse scapular ligament of scapula in Indian population. Int. J. Curr. Microbiol. App. Sci. 2014; 3(9): 1081-1084.
- [16]. Ashok Kumar Singh, Ritu. Ossification of Transverse Scapular Ligament in Population of Bihar & Its Clinical Implications. Journal of medical science and clinical research. 2018; 6(2): 1084-1089.
- [17]. J G Silva, M Abidu-Figueiredo, R M P Fernandes et al. "High incidence of complete ossification of the superior transverse scapular ligament in Brazilians and its clinical implications," International Journal of Morphology. 2007; 25(4): 855–859.
- [18]. Hrdlicka A. The adult scapula. Additional observations and measurements. Am J Phys Anthropol. 1942; 29(3): 363–415.
- [19]. Wang HJ, Chen C, Wu LP, Pan CQ, Zhang WJ, Li YK. Variable morphology of suprascapular notch: an investigation and quantitative measurements in Chinese population. Clin Anat. 2011; 24: 47-55.
- [20]. Polguy M, Jedrzejewski K, Majos A, Topol M. Variations in bifid superior transverse scapular ligament as a possible factor of suprascapular entrapment: an anatomical study. Int Orthop. 2012; 36(10): 2095–100.

How to cite this article:

Panjala Ashok, Shiny Vinila B H. STUDY ON THE INCIDENCE OF OCCURRENCE OF THE OSSIFICATION OF SUPERIOR TRANSVERSE SCAPULAR LIGAMENT WITH ITS CLINICAL IMPLICATIONS. Int J Anat Res 2019;7(4.2):7066-7069. DOI: 10.16965/ijar.2019.306