

Original Research Article

INCIDENCE OF PYRAMIDAL LOBE AND LEVATOR GLANDULAE THYROIDEAE OF THYROID GLAND IN ADULT CADAVERS: A MORPHOLOGICAL STUDY WITH ITS SURGICAL PERSPECTIVE

D. Kishorenaick ^{*1}, K. Thyagaraju ², B. Ravindra Kumar ³, V. Subhadra Devi ⁴.

^{*1} Tutor & PhD Scholar, Department of Anatomy, SVIMS-Sri Padmavathi Medical College For Women, Tirupati, Andhra Pradesh, India.

² Assistant Professor & PhD Scholar, Department of Anatomy, SVIMS-Sri Padmavathi Medical College For Women, Tirupati, Andhra Pradesh, India.

³ PhD Scholar, Department of Anatomy, Sri Venkateswara Institute of Medical Sciences, Tirupati, Andhra Pradesh, India.

⁴ Professor, Department of Anatomy, Apollo Institute of Medical Sciences, Chittoor, Andhra Pradesh, India.

ABSTRACT

Background: Thyroid gland a brownish red, highly vascular endocrine gland consisting of two lateral lobes connected by an isthmus. It lies in front of the second, third and fourth tracheal rings. It is one of the commonest glands well known for its developmental anomalies, ranging from common to rare ones. The thyroid surgeon must have full knowledge of the anatomy of the thyroid gland, including all of its embryological, congenital, or acquired variations. Levator glandulae thyroideae (LGT), the persistent part of thyroglossal duct (fibromusculoglandular) stretches from the pyramidal lobe or upper border of isthmus of thyroid gland to the body of the hyoid bone, usually on the left side. Presence of the pyramidal lobe (thyroid tissue remnant of embryological origin located in the pretracheal region between the isthmus and the hyoid bone), may impact completeness of thyroidectomy. These variations will help the surgeons in planning thyroid surgeries in a better and safe way.

Materials and Observations: Dissection was carried out routinely in 34 cadavers of both sexes in which 2 cadavers presented with LGT. In one cadaver LGT was extending from the left lobe of thyroid gland to hyoid bone. In the other cadaver in addition to the LGT, abnormal extent of the pyramidal lobe (PL). Thus accounting for an incidence of 5.80% variation, both the variations were noted in one male and one female cadavers.

Conclusion: In the present study occurrence of thyroid anomalies (morphological variations) such as pyramidal lobes along with LGT is vital, while dealing with thyroid surgeries in the neck region to avoid iatrogenic injuries during complete removal of the gland tissue. Knowledge of embryology of thyroid gland is vital as complex underlying embryology produces substantial anatomic variations both in thyroid bed and elsewhere in the neck and mediastinum.

KEY WORDS: Thyroid gland, Levator GlandulaeThyroideae[LGT], Thyroglossal duct, Isthmus, Pyramidal lobe, Hyoid bone.

Corresponding Author: D. Kishorenaick, Tutor & PhD Scholar, Department of Anatomy, SVIMS-Sri Padmavathi Medical College For Women, Tirupati, Andhra Pradesh, India.

E-Mail: kishorenaick@gmail.com

Access this Article online	Journal Information	
Quick Response code  DOI: 10.16965/ijar.2019.353	International Journal of Anatomy and Research RG Journal Impact: 0.21* ISSN (E) 2321-4287 ISSN (P) 2321-8967 https://www.ijmhr.org/ijar.htm DOI-Prefix: https://dx.doi.org/10.16965/ijar 	
	Article Information	
	Received: 20 Sep 2019	Accepted: 30 Jan 2020
	Peer Review: 21 Sep 2020	Published (O): 05 Apr 2020
	Revised: 13 Dec 2020	Published (P): 05 Apr 2020

BACKGROUND

Thyroid gland is highly vascular butterfly shaped and placed anteriorly in the lower part of the neck consisting of two symmetrical lateral lobes connected by a midline isthmus [1]. The gland is composed of right and left lobes, typically interconnected by an isthmus in the midline, lying anterolateral to the larynx and trachea at approximately the level of the second and third tracheal rings [2]. The normal thyroid gland weighs approximately 30 g. It is slightly heavier in women and becomes enlarged during pregnancy [3].

Embryology of Thyroid gland: The thyroid is the earliest of the pharyngeal derivatives to develop by about 24th day (4th week) of intrauterine life from a median endodermal thickening in the floor of the primitive pharynx [4,5] between tuberculum impar and copula at a point later indicated by foramen cecum [6]. As the embryo elongates and undergoes differential growth, the thyroid diverticulum migrates anteriorly and inferiorly to the hyoid bone tethered by a slender thyroglossal duct [7]. Consequently the thyroid descends in front of the pharyngeal gut as a bilobed diverticulum [6] and it soon converts into a solid cord and divides into right and left lobes, connected by the isthmus of the thyroid gland assumes its definitive shape by 7th week and reaches its final site in the neck. By this time the thyroglossal duct normally degenerates and disappears [5]. The embryological remnant of the caudal end of the thyroglossal duct commonly known as the pyramidal lobe often ascends from the isthmus or adjacent part of either lobe (more often from the left side) towards the hyoid bone [8]. Levator glandulae thyroideae, signify a persistent part of thyroglossal duct extending from the pyramidal lobe or upper border of isthmus of thyroid gland to hyoid bone, usually on the left side [5,1]. The present study is an approach to interpret the information on the morphology of LGT and PL of the thyroid gland and it may helps the surgeons, while dealing the neck region, to minimize the iatrogenic injuries.

MATERIALS AND METHODS

The study was carried out at the Department of Anatomy, SVIMS- Sri Padmavathi Medical with

34 well preserved Human Cadavers belonging to both sexes, during routine dissection hours for first MBBS students. As per Cunningham's Dissection Manual, A vertical incision was given on the skin from the chin to the sternum in the mid line. The subcutaneous fat and deep fascia was exposed; the infrahyoid muscles were identified and reflected laterally. The pretracheal fascia was removed and the right and the left lobe of the gland were identified.

The thyroid gland was examined carefully for the presence of isthmus, pyramidal lobe and LGT.

Fig. 1: Showing the Levator glandulae thyroideae (LGT) and Pyramidal Lobe (PL) of Thyroid Gland.

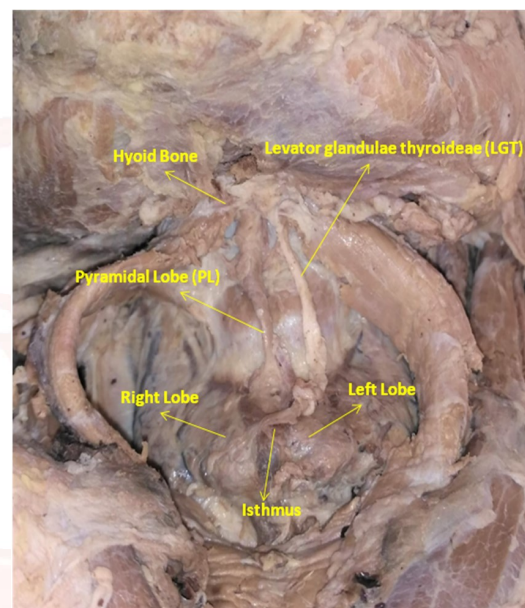
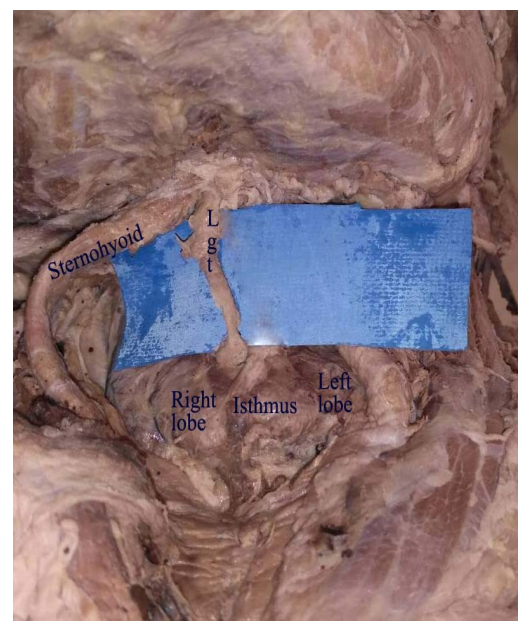


Fig. 2: Showing the Levator glandulae thyroideae (LGT), Right and Left lobes of Thyroid Gland.



When the pyramidal lobe was present, its position and extent was observed. If LGT present, noted its extent and in the cases presence of both LGT and PL, observed for the extent of the LGT in relation with the PL were also observed, and variations if any observed noted and related to the available literature and its clinical significance if any.

OBSERVATIONS AND RESULTS

In the present study Out of 34 cadavers observed (27 male and 7 females), In Two (2) cadavers found to possess LGT which accounted for 5.88% of the incidence. In the male cadaver aged around 55 years, the LGT was attached (caudally) to the left Pyramidal lobe just adjacent to the isthmus and the other (Cranial) end is attached to the lower border of the body of Hyoid bone (Fig. 1).

Table 1: Showing characteristics of embalmed cadavers.

Characteristics	Number	Percentage
Sex		
Male	27	79.40%
Female	7	20.58%
Thyroid gland		
Normal	32	94.10%
Abnormal	2	5.80%

In the other female cadaver of age 58 years, it was found the abnormal extent of the pyramidal lobe which is extending from the junction of the isthmus and the right lobe (caudally) and is connected to the body hyoid bone (cranially), we also observed that in the due course it also passing very close to the thyroid cartilage (right lamina) (Fig.2).

Pyramidal lobe and LGT were present in 7.93% cases situated to the left side of midline respectively and pyramidal lobe was extending from the isthmus to hyoid bone (Fig 1 and 2).

DISCUSSION

Thyroid gland consists of left and right lobes, which are attached by isthmus [11]. By 4th week of development endodermal thickening in the primitive pharynx turns thicker and undergoes differentiation before developing into thyroid primodium [15,18,19].

In the previous research conducted with different sample groups, with the miscellanies of the

cadavers' races, places and the period of study, revealed percentages of thyroid gland abnormality (18-66 %) that were higher than the one found in the present study [19, 11]. Thyroid gland abnormality found in the present study is a result of the emergence of pyramidal lobe (5.8 %). In the previous research conducted with different sample groups, with the diversities of the cadavers' nationalities and the places and the times of study, showed that the percentages of thyroid gland abnormality (18-66 %) were higher than the one found in this research [11-16]. In 2017, pyramidal lobe emergence case was reported [17] (Table 2). Pyramidal lobe was noted in 7 cadavers (13.4%) in the study of Venkata Chandrika Pitta et. al.,2019 [22]. Incidence of pyramidal lobe which is an embryological remnant of thyroglossal duct vary between 15 to 75% in anatomy literature according to Thews et.al.,1999 [24]. Prevalence of pyramidal lobe is noted in 50% cadavers in Bhatnagar et al.,1997 [25] study, in 28.9% cadavers in Harjeet A et al.,2004 [23], In the present study we observed the presence of LGT and PL both are extending upto body of the hyoid bone.

Levator glandulae thyroideae, signify a persistent part of thyroglossal duct extending from the pyramidal lobe or upper border of isthmus of thyroid gland to hyoid bone [1,5]. The occurrence rate of this found in this research (2.2 %) was relatively small compared to the rate found in other studies (between 15 to 62.4 %) [11,12,14,16,18]. Levator glandulae thyroideae was noted in 5% of cadavers in study done by Venkata Vinay Kumar M et al.,(2018) [20], in 36.6% cadavers in study done by Hemalatha et.al.,,2018 [21] and in 18.75% cadavers in study done by Anjan Jyoti Rajkonwar et.al.,2016 [12]. As per the study done by A. Harjeet et al (2004) [23] levator glandulae thyroideae is present in 19.8% cadavers. The presence of Levator glandulae thyroideae in the present study is comparable with previous studies as reported by Hemalatha et.al., 2018 [21] and Abhijeet Yadav et.al.,2014 [26].

In the present study, the abnormality of thyroid gland was found in male and female samples. However, the results obtained from the previous study showed the fibrous band is known as levator glandulae thyroideae it occur more in

Table 2: Abnormality of thyroid gland compared with other previous studies.

Authors	Country	Sample size	Pyramidal lobe %	LGT %	Pyramidal lobe combined with LGT %
Ranadeet al. (2008) [11]	Southern India	105	58	49.5	21.6
Maneenin.C et.al(2019) [10]	Northeastern Thai	45	8	2.2	8.8
Rajkonwar&Kusre (2016) [12]	Northeast India	80	38.7	8.7	--
Gurleyiket al. (2015) [13]	Turkey	166	65.7	--	--
Veerahanumaiah et al. (2015) [14]	Mysore (India)	89	46	41	--
Mortensen et al. (2014) [15]	United kingdom	416	21.6	--	--
Prakash et al. (2012) [16]	Karnataka (India)	70	66	62.4	--
Braun, et al. (2007) [19]	Austria	58	55	--	--
Begum et al. (2009) [18]	Bangladesh	60	26.7	15	--

males [3,5]. Thyroid gland abnormality found in this research was the combined abnormality of pyramidal lobe and Levator glandulae (5.8%). In another study, this abnormality was found to be 8.8% as compared in the study of Maneenin. C et.al.,2019 [10] in north eastern Thailand population and 21.6 % Ranade *et al.*,2008 [11] in southern India. thyroid gland defects are vulnerable to the operation of radiology physicians and surgeons while performing thyroidectomy and tracheostomy [13,17].

Comprehensive acquaintance of normal anatomy of thyroid gland and its variations are indispensable to precise the diagnosis of ailment and also to accomplish effective and harmless surgery that is possibly seen in the study.

Limitation: This type of study can be done in all age groups; but present study focused only on adult cadavers. We have only used dissection as a tool for the study but radiological techniques like MRI, CT scan and Ultrasonography, Histopathology could give more details of the abnormal tissue, further more future studies may conducted with use of mentioned methods for better understanding the case.

CONCLUSION

The purpose of this study is to highlight different anatomical variations with respect to the thyroid gland and thereby, to form a basis for safe and effective surgeries and therefore can interpret the information on the morphology of the thyroid gland and help the clinicians in their practice. All through surgery identification of lobes, vessels and anomalies are essential so that total removal of pathology is probable without leaving any residual disease.

Conflicts of Interests: None

REFERENCES

- [1]. Stranding S. Gray's anatomy, Churchill Livingstone, Elsevier, 40th ed2008; 462.
- [2]. Ozgur Z, Celik S, Govsa F, et al: Anatomical and surgical aspects of the lobes of the thyroid glands. *Eur Arch Otorhinolaryngol* 2011;268:1357- 1363.
- [3]. Gray H, Clemente CD. Anatomy of the Human Body (American ed 30). Philadelphia, PA, Lea and Febiger, 1985.
- [4]. Pansky B. Review of medical embryology, Macmillan Publishing Co., New York, 1982; 136-7.
- [5]. Moore KL, Persaud TVN & Torchia, M. G. The developing human: Clinically oriented embryology, 9th edition, Philadelphia, Elsevier,2013; pp.173-4.
- [6]. Sadler TW. Langman's medical embryology: Head and Neck.9th edition, Lippincott Williams and Wilkins, Philadelphia, 2004;363-402.
- [7]. Hansen JT. Embryology and surgical anatomy of the lower neck and superior mediastinum. In: Falk SA. (Editor), Thyroid disease: Endocrinology, surgery, Nuclear Medicine, and Radiotherapy, 2nd edition, Lippincott-Raven Publishers, Philadelphia,1997;15-27.
- [8]. Sinnatamby CS. Last's anatomy, Churchill Livingstone Elsevier, 11thEd- 2006:351-352.
- [9]. G.J. Romanes, Cunningham's Manual of Practical Anatomy Vol-2 Abdomen,15th edition.
- [10]. Maneenin.C, Maneenin.N, Iamsaard, S. Anatomical variations of thyroid glands in Northeastern-Thai embalmed cadavers. *Int. J. Morphol.*, 2016;37(1):136-140.
- [11]. Ranade, A. V, Rai R, Pai M. M, Nayak S. R, Prakash. Krisnamurthy, Narayana S. Anatomical variations of the thyroid gland: possible surgical implications. *Singapore Med. J.*, 2008;49(10):831-4.
- [12]. Rajkonwar, A. J. & Kusre, G. Morphological variations of the thyroid gland among the people of upper Assam region of Northeast India: a cadaveric study. *J. Clin. Diagn. Res.*, 2006;10(12):AC01-03.
- [13]. Gurleyik, E.; Gurleyik, G.; Dogan, S.; Cobek, U.; Cetin, F. & Onsal, U. Pyramidal lobe of the thyroid gland: surgical anatomy in patients undergoing total thyroidectomy. *Anat. Res. Int.*, 2015;384148.

- [14]. Veerahanumaiah, S, Dakshayani, K. R, Menasinkai, S. B. Morphological variations of the thyroid gland. *Int. J. Res. Med. Sci.*, 2015;3(1):53-7.
- [15]. Mortensen, C.; Lockyer, H. & Loveday, E. The incidence and morphological features of pyramidal lobe on thyroid ultrasound. *Ultrasound*, 2014;22(4):192-8.
- [16]. Prakash Rajini T. Ramachandran A, Savalgi G. B, Venkata S. P, Mokhasi V. Variations in the anatomy of the thyroid gland: clinical implications of a cadaver study. *Anat. Sci. Int.*, 2012;87(1):45-9.
- [17]. Kaklamanos I, Zarokosta M, Flessas I. Zoulamoglou M, Katsoulas T, Birbas K, Troupis T, & Mariolis-Sapsakos T. Surgical anatomy of double pyramidal lobe on total thyroidectomy: a rare case report. *J. Surg. Case Rep.*, 2017;(3):rjx035.
- [18]. Begum M, Khatun M, Kishwara S, Ahmed R, Naushaba J. A postmortem study of the pyramidal lobe of the thyroid gland in Bangladeshi people. *J. Dhaka Med. Coll.*, 2009; 18(2):120-3.
- [19]. Braun E. M, Windisch G, Wolf G, Hausleitner L, Anderhuber F. The pyramidal lobe: clinical anatomy and its importance in thyroid surgery. *Surg. Radiol. Anat.*, 2007;29(1):21-7.
- [20]. Venkata Vinaya Kumar M, Reshma Mohammad, Sreelatha S. International journal of Anatomy, Radiology and Surgery. 2018;7(2):9-13.
- [21]. Hemalatha G, Subba Rao M. Anatomical variations of thyroid gland and its clinical significance. *IOSR Journal of dental and medical sciences*. 2018;17(9):22-24.
- [22]. Venkata Chandrika Pitta, Laxmi Durga Jakka, Lalitha Balla, Syamala Gollamandala. Anatomical variations of thyroid gland - A cadaveric study. *MedPulse – International Journal of Anatomy*. July 2019;11(1): 05-10.
- [23]. Harjeet A, Sahni D, Indar J, Aggarwal AK. Shape, measurements and weight of thyroid gland in north-west Indians. *Sur Radiol Anat* 2004;26:91-95.
- [24]. Thews G, Mutschler E, Vompel P. Anatomie Physiologie Pathophysiologie des Menschen. Wissenschaftliche Verlagsgesellschaft mbH, Stuttgart, 1999;491-496.
- [25]. Bhatnagar K, Nettelton GS, Wagner C. Subisthmic accessory thyroid gland in man: a case report and a review of thyroid anomalies. *Clin. Anat* 1997;10:341-344.
- [26]. Abhijeet Joshi, Sumit Gupta, V H Vaniya. Anatomical variations in the origin of superior thyroid artery and its relation with external laryngeal nerve. *National journal of medical research*. 2014;4(2):138-141.

How to cite this article: D. Kishorenaick, K. Thyagaraju, B. Ravindra Kumar, V.Subhadra Devi. INCIDENCE OF PYRAMIDAL LOBE AND LEVATOR GLANDULAE THYROIDEAE OF THYROID GLAND IN ADULT CADAVERS: A MORPHOLOGICAL STUDY WITH ITS SURGICAL PERSPECTIVE. *Int J Anat Res* 2020;8(2.1):7458-7462. **DOI:** 10.16965/ijar.2019.353