

MORPHOMETRIC STUDY OF HUMAN FOETAL THYMUS

Vaishali Sitaram Kirwale ¹, S. S. Dhapate ^{*2}.

¹ Assistant Professor, Department of Anatomy, Government Medical College, Aurangabad, Maharashtra, India.

^{*2} Professor and Head, Department of Anatomy, S.R.T.R Medical College, Ambajogai, Beed, Maharashtra, India.

ABSTRACT

Introduction: Thymus consists of two pyramidal lobes. It is located in the mediastinum behind the sternum and in front of the pericardium and great vessels of the heart. The present study has been undertaken to highlight some important points in morphometry of foetal thymus gland.

Materials and Methods: In the present study 30 fetuses (12-38 week) were studied. The obtained fetuses were fixed in 10% formalin. After proper fixation they were subjected to dissection. The length and breadth of gland was measured by vernier caliper in centimeters. Weight of the gland was measured using electronic weighing machine. Naked eye examination done for number of lobes.

Results: The average length of the thymus at 12th week was 0.2cm on right side and 0.2cm on left side, it was increased to 4cm on right side and 4.5cm on left side. The average breadth of thymus was 0.12cm on right side and 0.10cm on left side at 12th week which was increased to 2.2cm and 2.6cm on right & left side respectively at 38th week. The average weight of thymus was 0.1 gm at 12th week and 8.2 gm at 38th week. The majority of thymus 26(86.67%) shows presence of two lobes.

Conclusion: All parameters length, breadth and weight of thymus show gradual increase with advancing gestational age with significant changes. There are wide variations in number of lobes of thymus gland.

KEY WORDS: Thymus, morphometry, fetuses, gestational age.

Corresponding Author: Dr. Shankar S. Dhapate, Professor and Head, Department of Anatomy, S.R.T.R Medical College Ambajogai, Beed, Maharashtra, India. **E-Mail:** anasrtr@rediffmail.com

Access this Article online	Journal Information
Quick Response code  DOI: 10.16965/ijar.2020.120	International Journal of Anatomy and Research RG Journal Impact: 0.21* ISSN (E) 2321-4287 ISSN (P) 2321-8967 https://www.ijmhr.org/ijar.htm DOI-Prefix: https://dx.doi.org/10.16965/ijar 
	Article Information
	Received: 06 Feb 2020 Peer Review: 06 Feb 2020 Revised: None
	Accepted: 02 Mar 2020 Published (O): 05 Apr 2020 Published (P): 05 Apr 2020

INTRODUCTION

Interest in human development is very wide spread largely because of the curiosity about our beginnings and desire to improve the quality of life. Human development begins at fertilization when a male gamete or sperm unites with a female gamete or oocyte to form a single cell, a zygote. With the formation of zygote (single celled stage), fetal development begins. Cell division, cell migration, programmed cell death, differentiation; growth

and cell rearrangement transform this zygote into a multicellular human being [1].

The word thymus comes from the Latin derivation of the Greek word thymos, meaning "warty excrescence." Because thymos also means "soul" or "spirit," the thymus was misrepresented as the seat of the soul by ancient Greeks. Galen[2] of Pergamum (130-200A.D.), who first noted that thymus was proportionally largest during infancy, referred to the thymus as the "organ of mystery" [3].

Towards the end of sixth week each third pharyngeal pouch shows a pronounced ventral sacculation, and the entire pouch is set free in the week following. At first hollow, these thymic primordia rapidly becomes solid epithelial bars. The lower end enlarge and unite superficially during the eighth week to foreshadow the definitive organ[4]. Defective pathway of the embryological descent of the thymic primordia may lead to a clinical spectrum of anomalies of the thymus [5].

Ectopic thymic tissue is found in 25% of the population [6]. Ectopic thymic tissue may lead to development of some lesion like a solid mass representing ectopic thymic tissue, thymic cyst and cervical thymoma[7].

Thymus consists of two pyramidal lobes. It is located in the mediastinum behind the sternum and in front of the pericardium and great vessels of the heart in the adult. The primordia of thymus develop in the region of superior neck in early fetal life and reach final destination in the mediastinum by progressive descent[8].

At birth the thymus is most often bilobar. The thickest part of the gland at birth is not at superior thoracic aperture but lies immediately above the base of heart. The right lobe of thymus measures c.9mm and left c.11mm in normal children's. After the age of 20 years it decreases to c.5-6mm in thickness[9]. The breastfeed infants had thymuses on an average twice the size of those in formula fed infants[10].

The present study has been undertaken to highlight some important points in morphometry of normal human foetal thymus gland.

MATERIALS AND METHODS

Morphometric study of thymus gland in human foetuses of various gestational ages was carried out in the department of anatomy in collaboration with department of obstetrics and gynaecology during the academic year 2013-2015.

In the present study 30 normal foetuses were obtained from the department of obstetrics & gynaecology government medical college and hospital with the permission of professor & head of department. These fetuses included the spontaneous abortus and still born. For the above

purpose the approval was also taken from the local ethical research committee.

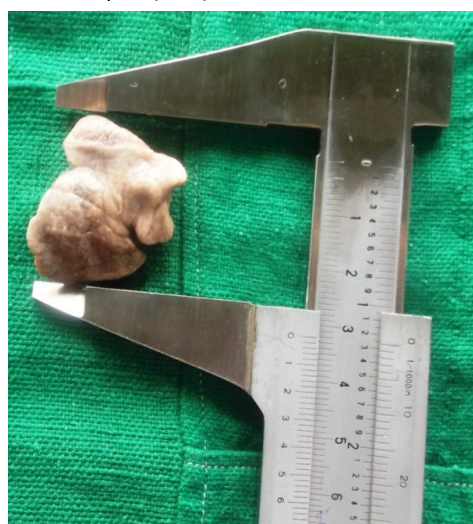A full anatomical examination was performed in all specimens to document normal anatomical development. A standard proforma was designed and used to maintain a protocol in selecting only the normal foetuses. Thus, this helped avoiding any kind of bias in the current study. Twin foetuses and foetuses with gross anomalies were omitted from the study. Foetuses were collected within 3-4 hours immediately after the delivery to avoid post-mortem changes.

The fixation of the foetuses was ensured by injecting 10% formalin locally on various sites with the help of 10ml syringe and 20 no. needle in cranial cavity, thoracic cavity, in the neck and subcutaneously in upper and lower limbs. All the fetuses were carefully dissected after allowing them to fix for a period for 7-15 days after undertaking the process of embalming. [Fig. 1]

Fig. 1: Dissection Showing Thymus Gland In situ of 36 week foetus.




Fig. 2: Showing measurement of Thymus Gland (36 week) by Vernier caliper (cms).



Measurements of External parameters: The length of gland was measured from above downwards by vernier caliper in centimeters. The breadth of the gland was measured by vernier caliper in centimeters. [Photo 2] Weight of the gland was measured using electronic weighing machine. The gland was observed with naked eye for presence of number of lobes.

OBSERVATIONS AND RESULTS

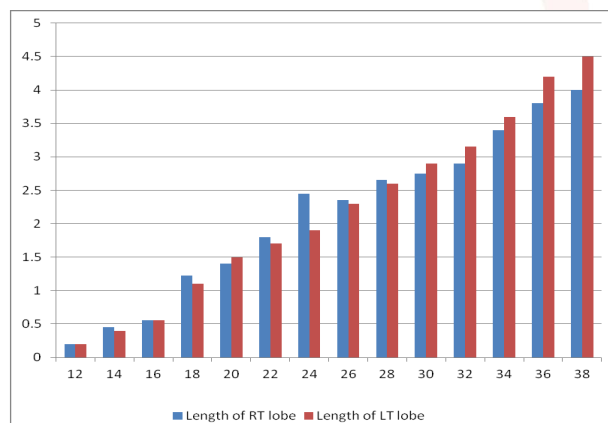
The following are the parameters studied;

1. Length of right and left lobe of thymus
2. Breadth of right and left lobe of thymus
3. Weight of thymus
4. Number of thymic lobes

For the purpose of study and comparison with other researchers the fetuses were divided into 14 groups initially. When there was more than one fetus in a particular group, the average was calculated for that group. The parameters were studied in the normal fetuses which were procured and the data was collected, tabulated and analyzed statistically.

Length of thymus gland: Length of the thymus gland was measured in each foetus by using vernier caliper (in cm). When there was more than one foetus of the same gestational age, average length calculated for that particular age group. It was observed that the length of thymus gland at 12th week of gestation was **0.2cm** on right side and **0.2 cm** on left side. It was increased to **4cm** on right side and **4.5cm** on left side at the 38th week of gestation. By using this data, graph was plotted. (Graph 1)

Graph 1: Average gland length at different gestational age.



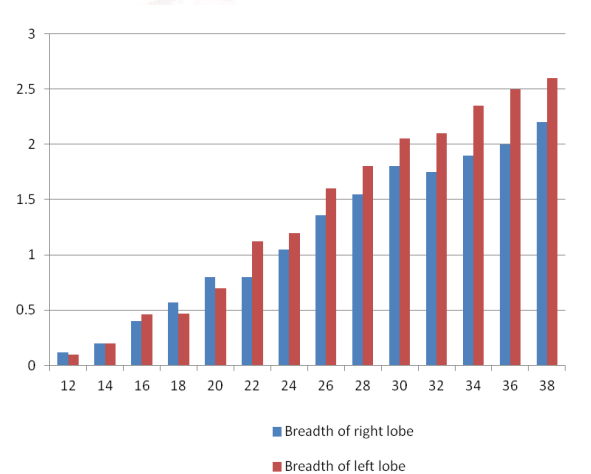
X-axis-Gestational age in weeks

Y-axis—Length in centimeter

This graph shows that average length of both the lobes of thymus increases with increase in gestational age. The length of left lobe of is relatively greater than right lobe 30week onwards.

Breadth of Gland: Breadth of the thymus gland was measured in each fetus by using vernier caliper (cm). When there was more than one fetus of the same gestational age, the average breadth calculated for that particular age group. The obtained data was tabulated in It was observed that the breadth of thymus gland at 12th week of gestation was **0.12cm** on right side and **0.1 cm** on left side. It was increased to **2.2cm** on right side and **2.6cm** on left side at the 38th week of gestation. By using this data, graph was plotted. (Graph 2)

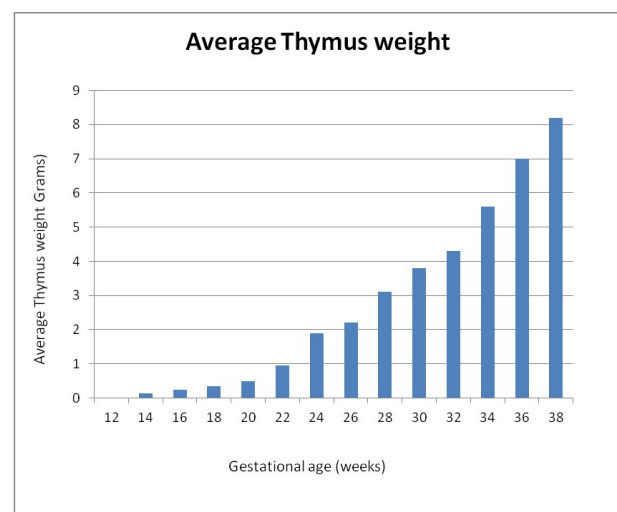
Graph 2: Average gland breadth at different gestational ages.



X-axis- Gestational age in weeks

Y-axis- Breadth in centimeter

Graph 3: Average thymus gland weight at different gestational ages.



X-axis - Gestational age (weeks)

Y-axis - Average Thymus weight (grams)

This graph shows that average breadth of both the lobes of thymus increases with increase in gestational age. The breadth of left lobe of is relatively greater than right lobe 22week onwards.

Weight of Thymus Gland: The weight of thymus gland was measured in each fetus by using electronic weighing machine. It was observed that the weight of thymus gland was **0.1 gm** at 12th week of gestation and it increased to **8.2 gm** at the 38th week of gestation.

By using this data, graph was plotted. (Graph 3) This graph shows that average weight of the thymus increases with increase in gestational age.

Number of thymic lobes: In the present study thymus glands were observed for the presence of number of lobes. The two lobes were present in majority of glands about 26 (86.67%). Three glands 3 (10%) shows presence of three lobes. Only 1 (3.33%) was having four lobes whereas glands with single lobe did not observed in the present study.

DISCUSSION

The present study was carried out with an attempt to delineate the proper development of the human foetal thymus gland. Different morphometric parameters were included in the study in order to elaborate the developmental changes in the thymus gland. The thymus gland was studied in the intrauterine life of a foetus from a period of 12 weeks of gestation till term.

Differences in studies and conclusions exist on account of different authors regarding the dimensions of thymus gland were discussed on the basis of observations and results obtained during the course of the study. Further, these findings were compared with established literature and with the observations of researchers who have undertaken the study of thymus gland in the past.

As mentioned earlier the various parameters which were studied are analysed in relation to the thymus gland.

Length of thymus gland: The length of the foetal thymus at different gestational age was measured in centimeters. The findings of the

present study showing calculated mean and standard deviation were tabulated in the table no.1

Table 1: Mean length and standard deviation of gland at different gestational age groups.

Fetal group (weeks)	Gland Length(cm)	
	Present Study (mean & std.dev)	
	Right lobe	Left lobe
12-20	0.8272 \pm 0.4839	0.7818 \pm 0.4423
21-28	2.2454 \pm 0.3933	2.0454 \pm 0.3670
29-38	3.2375 \pm 0.5012	3.5 \pm 0.6071

The findings of length of thymus (right & left lobe) were compared with the results of previous worker.

K.Vijaya lakshmi et al [11] concluded that length of right lobe of thymus in group I,II and III was 0.6727, 1.6625 and 3.605 respectively. These findings are more or less similar with the findings of present study.

Mamta Rani et al [12] stated that mean length of right lobe of thymus was (0.98 \pm 0.47) in group I (upto 20wks), (1.63 \pm 0.33) in group II (21-30wks) and (3.94 \pm 1.05) in group III (31-40wks). These findings shows similarity in group I and group III findings of present study.

Yekeler et al [13] reported the maximum craniocaudal length of thymus which was (31.2 \pm 4.4)cm in 31-40 week fetuses.

The findings of length of left lobe were also compared with k Vijaya Lakshmi et al [11], (0.55, 1.79, 3.74) and Mamta Rani et al [12], (0.90, 1.65, 3.86) in all three groups. These findings are more or less similar to the findings of present study.

Breadth of thymus gland: The breadth of the fetal thymus at different gestational age was also measured in centimeters.

Table 2: Mean breadth and standard deviation of gland at different gestational age groups.

Fetal group (weeks)	Gland Breadth (cm)	
	Present Study (mean & std.dev)	
	Right lobe	Left lobe
12-20	0.4381 \pm 0.2307	0.4090 \pm 0.2022
21-28	1.1545 \pm 0.3142	1.3545 \pm 0.2944
29-38	1.875 \pm 0.1908	2.2625 \pm 0.2263

K.Vijaya Lakshmi et al [11] found that breadth of right lobe of thymus was 0.2636, 0.6562, 3.1 in group I,II and III respectively whereas it was 0.4381, 1.1545, 1.875 in present study. The

values of gland breadth given by K.Vijaya Lakshmi[11] shows difference in the means of second and third (21-28 & 29-38) group in present study.

Aksh Dubey et al.[14] conducted a study by measuring transverse diameter of fetal thymus and concluded that average transverse diameter of right lobe of fetal thymus at 12th week of gestation was 6.2 mm which was increased to 17 mm at 38th week.

Mamta Rani et al[12] concluded that maximum breadth of right lobe of Thymus was (0.40±0.14), (0.87±0.29) and (3.34±0.70) in group I, II and III respectively.

Whereas present study shows that average breadth of right lobe of thymus at 12th week was 0.12cm (1.2mm) which was increased to 2.2cm (22mm) at 38th week.

The breadth of left lobe of gland at different gestational age groups were compared with previous authors. The findings of group I, II and III were 0.30, 0.61, 3.27 reported by K Vijaya Lakshmi[11] whereas it was 0.40, 1.35 and 2.26 in the present study. It was seen that the values of gland breadth given by K.Vijaya Lakshmi was more or less similar to the findings of the present study upto 20 weeks only.

Aksh Dubey et al[14] concluded that average transverse diameter of left lobe of fetal thymus at 12th week of gestation was 4.3 mm which was increased to 22 mm at 38th week.

The maximum transverse diameter of left lobe of Thymus in group I, II and III was (0.44±0.23), (0.72±0.40) and (3.46±0.58) respectively reported by Mamta Rani et al[12].

Yekeler et al[13] concluded that maximum transverse diameter of thymus was found to be of mean value 29.3±3.3 mm in fetuses of 31-40 weeks.

Present study shows that average breadth of left lobe of thymus at 12th week was 0.10cm (1.0mm) which was increased to 2.6cm (26mm) at 38th week.

Weight of thymus gland:

The weight of thymus gland at different gestational age was also measured in grams. The gland weight at 12 weeks gestation is 0.1 grams whereas it was increased to 8.2 grams at 38

weeks of gestation.

Table 3: Mean weight and standard deviation of gland at different gestational age groups of present study.

Fetal group (weeks)	Gland Weight (gm)
12-20	0.27 ± 0.1371
21-28	1.85 ± 0.8347
29-38	5.32 ± 1.6385

The average values of gland weight given by K.Vijaya Lakshmi[11] were 0.40, 2.21, 6.76 gm in group I, II and III whereas it was 0.27, 1.85, 5.32 in three groups of present study. These findings are more or less similar to the findings of the present study with slight difference in the means of individual group.

The weight of thymus in group I was (0.594±0.336), in group II was (1.99±0.88) and (8.56±3.01) in group III stated by Mamta Rani et al[12] which shows wide difference in group III gland weight with present study.

Number of thymic lobes: The percentage incidence of number of thymic lobes of present study was compared with Krishnamurthy et al[8] (Table 4).

Sr.no	No. of lobes	Krishnamurthy et al	Present study
1	Two	74%	86.67%
2	Three	13%	10%
3	Four	13%	3.33%
4	Single	0%	0%

The incidence of two lobes thymus was largest (74%) in the glands studied by Krishnamurthy[8] and also in the present study which was (86.67%) among 30 thymus studied.

CONCLUSION

All the parameters Length, Breadth and Weight shows gradual rise in relation to gestational age with significant changes. The thymus shows wide morphological variations in its number of lobes. These parameters and variations are very helpful for the radiologists in imaging and for surgeons during thymectomy.

Conflicts of Interests: None

REFERENCES

- Moore KL, Persaud. The Developing human: clinically oriented embryology 8th ed. Philadelphia: W. B. Saunders Company; 2008. p. 179.
- Galen. Galen on the usefulness of the parts of the body Ithaca. Cornell University Press (New York) 1968: 30.

- [5]. Seid Abbas Tabatabaie, Seid Mozafar Hashemi, Behnam Sanei, Mohammad Hossein Sanei, The frequency of ectopic thymic tissue in the necks of patients without any thymic disease, © Med Sci Monit, 2007; 13(6): CR283-285
- [6]. Goldstein G, Scheid M P, Boyse E A, Schlesinger D H, van Vauwe J.(1979).A synthetic pentapeptide with biological activity characteristic of the thymic hormone thymopoietin. Science 204: 1309–1310.
- [7]. Nowak PA, Zarbo RJ, Jacobs JR: Aberrant solid cervical thymus. Ear Nose Throat J, 1988; 67: 670
- [8]. Krishna Murthy,V.Subadra Devi. Morphological features of human thymus gland from foetal to old age. International journal of biological and medical research. 2010; 3(2):1502-1505.
- [3]. Mizuki Nishino, Simon K. Ashiku, Olivier N. Kocher, Robert L. Thurber, Phillip M. Boiselle, HirotoHatabu. The Thymus: A comprehensive Review. Radio Graphics 2006; 26: 335-348.
- [4]. Arey LB. Developmental anatomy. 6th ed. Philadelphiaand London: WB Saunders company;1956: 21-23, 234-236.
- [9]. Standring S, Borely NR, Collins P, Crossman AR, Gatzzoulis MA, Healy JC, et al. Gray's Anatomy. 40th ed. Chrchill Livingstone Elsevier publisher; 2008.p. 945-49.
- [10].Hasselbalch H, Jeppesen DL, Engelmann MDM, Michaelsen KF & Nielsen MB(1995). Decreased thymus size in formula-fed infants compared with breastfed infants. Acta Paediatrica 85: 1029–1032.
- [11]. K. Vijaya Lakshmi, B. Narasinga Rao and M. Pramila Padmini. Histo-Morphogenesis of Thymus in Human Foetuses. International Jouranal of Basic and Applied Medical Sciences.2012: 2(2):78-82.
- [12]. Mamta Rani, Nityanand Srivastava, Anuj Jain, Adil ashgar. Study of Morphological Features of Thymus Gland In Human Foetuses At Different Age Group IOSR Journal of Dental and medical Sciences (IOSR-JDS); 17(7), 2018: 31-37.
- [13]. Yekeler E, Tambag A, Tunaci A, Genchellac H, Dursun M, Gokcay G, Acunas G. Analysis of the thymus in 151 healthy infants from 0 to 2 years of age. Ultra-sound Med 2004;23(10):1321–1326
- [14]. Dubey Aksh, Jethani SL, Singh Deepa. A Study of Correlation between Transverse diameter of fetal thymic lobes and gestational age. International Journal of Research in health Sciences. 2014;2(2)715-719.

How to cite this article:

Vaishali Sitaram Kirwale, S. S. Dhapate. MORPHOMETRIC STUDY OF HUMAN FOETAL THYMUS. Int J Anat Res 2020;8(2.1):7424-7429. DOI: 10.16965/ijar.2020.120