International Journal of Anatomy and Research,
Int J Anat Res 2013, Vol 1(2):78-82. ISSN 2321- 4287

Case Report

BILATERAL MULTIPLE VARIATIONS IN THE FORMATION OF THE BRACHIAL PLEXUS AND ITS TERMINAL NERVES: A CASE REPORT

Gabriel J Mchonde[1]*, Flora M Fabian[2], Hortensia G Nondoli[3].

[1]* PhD Student, Department of Cell Biology and Neuroanatomy, School of Medicine, Iwate Medical University, Japan.

[2] Professor of Anatomy, Department of Anatomy and Histology, School of Medicine, International Medical and Technology University.

[3] Lecturer, Department of Anatomy and Histology, School of Medicine, International Medical and Technology University.

ABSTRACT

Background: Variations in formation of brachial plexus roots, trunks, divisions and cords are not uncommon and maybe of important in regional anaesthesia involving the upper limb. However, in the present case we are reporting a rare bilateral multiple variations observed during routine dissection on a 77-years-old embalmed male cadaver on left and right brachial plexus. Understanding the anatomical variations involving brachial plexus is important and might benefit the physicians, surgeons, anaesthesiologists and neuroanatomists during their routine procedures involving the cervical, axillary and the upper limb regions.

KEY WORDS: BRACHIAL PLEXUS; TRUNKS; TERMINAL NERVES; VARIATIONS.

Address for Correspondence: Dr. Gabriel J Mchonde, Department of Cell Biology and Neuroanatomy, School of Medicine, Iwate Medical University, Iwate, Japan. Nishitokuda 2-1-1, Yahaba-cho, Shiwa-gun, 028-3694, **Contact no**.+81 80 6293 4529.
E-Mail: gmchonde@yahoo.co.uk or mchonde@iwate-med.ac.jp

Access this Article online

Quick Response code

Web site: International Journal of Anatomy and Research
ISSN 2321-4287
www.ijmhr.org/ijar.htm

Received: 28 July 2013
Peer Review: 29 July 2013 Published (O):06 Sep 2013
Accepted: 19 Aug 2013 Published (P):30 Sep 2013

BACKGROUND

Brachial plexus is a principle somatic nerve plexus supplying the upper limb situated in the posterior triangle of the cervical region and in the axillary region. This plexus is a result of union of anterior rami of inferior four cervical nerves (C5, C6, C7, and C8) and the anterior ramus of the first thoracic nerve (T1). In normal anatomy, the brachial plexus is described to have roots, trunks, divisions, cords and terminal nerves [3, 6]. At the lateral border of the anterior scalene muscle, the C5 and C6 roots unite to form the superior trunk, C7 forms middle trunk, and C8 and T1 unites to form the inferior trunk, each of which splits into anterior and posterior divisions in the floor of the posterior triangle of the neck. At the upper border of the first rib, these divisions form cords which are related to the second part of the axillary artery. All posterior divisions join to form posterior cord (C5 to T1), anterior divisions of the superior and middle trunks join to form lateral cord (C5 to C7), and anterior division from inferior trunk forms the medial cord (C8 to T1). Just distal to the inferior border of the pectoralis minor muscle, near the third part of the axillary artery, the cords give off their terminal branches, including the axillary, musculocutaneous, radial, median, and ulnar nerves [8].

Variations involving the brachial plexus has been reported and discussed by many researchers [2, 6, 7] and they were found to involve different

parts of it. However, in the present study we are reporting a novel finding that involve bilateral multiple variations linking the roots, trunks, cords of the brachial plexus and the pectoral, median, ulna, radial, and axillary nerves observed during the routine dissection class of the undergraduate medical students. Understanding these anatomical variations of the brachial plexus, will append to existing knowledge explaining its morphological and clinical significance.

CASE REPORT

During routine dissection classes of undergraduate medical students, we observed bilateral variations in a 77-years-old male cadaver involving the trunks, cords and the terminal nerves of the brachial plexus.

The posterior triangle of the neck and the axillary region of the right and left upper limb were dissected and superficial and deep fascia removed.

FIGURE 1: LEFT BRACHIAL PLEXUS

Figure 1: Photograph from 77-years-old embalmed male cadaver showing the ventral view of left brachial plexus roots and trunks. Note the formation and course of trunks. **C3-C8:** ventral rami of the third to eighth cervical spinal nerves; **T1:** ventral rami of first thoracic spinal nerve; **ST:** superior trunk;**MT:** middle trunk; **IT:** inferior trunk; **SV:** subclavian vein; **SA:** subclavian artery; **CA:** left common carotid artery; **Vn:** vagus nerve; **Ph:** phrenic nerve; **IJV:** internal jugular vein; **SupsA:** suprascapular artery.

Variations in the left brachial plexus:

Formation of the trunks

Unusual variations were observed in the formation of middle and inferior trunks of the brachial plexus. We noticed roots C7-C8 joined to form middle trunk of the left brachial plexus and travel superior to subclavian artery towards the axillary region (**Figure 1**). The inferior trunk was formed solely by root T1 and passes inferior to subclavian artery (**Figure 1**). Roots C5-C6 joined in a usual manner to form superior trunk.

Figure 2: LEFT BRACHIAL PLEXUS

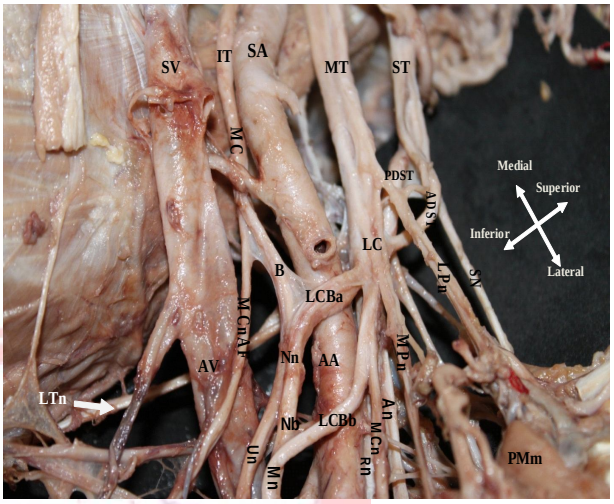

Figure 2: Photograph from 77 years old male cadaver showing the left brachial plexus. Note the Inferior trunk **(IT)** was formed as the continuation of first thoracic nerve **(T1)**, the middle trunk **(MT)** formed by the union of eighth cervical nerve **(C8)** and seventh cervical nerve **(C7)**. The lateral cord **(LC)** formed by roots C5-C8, gave two branches; Lateral cord branch one **(LCBa)** that joined an upper branch from medial cord **(B)** to form nerve trunk **(Nn)**. The Nn then gave out an Ulna nerve **(Un)** and a branch **(Nb)** that united with a second branch from the lateral cord **(LCBb)** to form the median nerve **(Mn)**. (**SV:** Subclavian vein, **SA:** Subclavian artery, **AA:** Axillary artery, **AV:** Axillary vein, **ST:** superior trunk, **PDST:** posterior division of superior trunk, **ADST:** anterior division of superior trunk, **SN:** supraclavicular nerve, **LPn:** lateral pectoral nerve, **MPn:** Medial pectoral nerve, **An:** Axillary nerve, **MCn:** musculocutaneous nerve, **Rn:** Radial nerve, **MCnAF:** medial cutaneous nerve of the arm and forearm, **LTn:** long thoracic nerve, **MC:** medial cord, **PMm:** pectoralis minor muscle).

Formation of cords

The superior and middle trunks subdivided into posterior and anterior divisions; while inferior trunk did not divide it descends as a solitary cord. Posterior divisions from superior and middle trunks joined to form posterior cord (C5, C6, C7 and C8). Anterior divisions from the superior and middle trunks joined to form the lateral cord (roots C5, C6, C7 and C8). Medial cord (T1) was noticed as it was formed solely by the inferior trunk formed by root T1 and descends inferomedially to axillary artery into the axillary region (**Figure 2**).

It gave off two branches; upper and lower branches. Upper branch descends laterally and joined a branch from lateral cord. Lower branch continued as a common trunk which later gave off medial cutaneous nerve of the arm (root T1) and the forearm (root T1 in **Figure 2**).

Formation of terminal nerves

In our observations on the terminal nerves we noticed variations on their formation which involved the source of origin.

The lower branch of the medial cord subdivided into two branches: Medial cutaneous nerve of the arm (T1) and medial cutaneous nerve of the forearm (T1 in **Figure 2**). The upper branch of the medial cord joined the first branch from lateral cord (LCBa) to form a common nerve trunk (Nn) which gave off a nerve branch (Nb) that joins the second branch from the lateral cord (LCBb) forming a median nerve (C5, C6, C7, C8 and T1), then continued as the ulna nerve (C5, C6, C7, C8 and T1 in **Figure 2**).

Lateral pectoral nerve (roots C5, C6, C7, and C8) was noticed to arise from the union of branches from anterior divisions of the middle trunk (C7, C8) and superior trunk (**Figure 2**).

Medial pectoral nerve (roots C5, C6, C7 and C8) was noticed to arise as the first branch from the lateral cord (**Figure 2**).

Musculocutaneous nerve (roots C5, C6, C7 and C8) was observed to arise as the terminal branch of the lateral cord after giving off the two branches; LCBa and LCBb (**Figure 2**).

The terminal nerves originated from the posterior cord were formed solely by nerve fibers from the superior (C5, C6) and middle (C7, C8) trunks without receiving any contribution from the inferior trunk (T1).

Variations in the right brachial plexus

On the right upper limb the trunks was formed as described on the left side. However, the root T1 passes posterior then superior to the subclavian artery forming the inferior trunk (root T1). It gave off the posterior and anterior divisions (**Figure 3**). Posterior divisions from all the trunks joined to form the posterior cord.

Terminal nerves were formed in a similar manner as described on the left upper limb brachial plexus with the exception of the medial and lateral pectoral nerves.

Right medial pectoral nerve (T1) originated from the medial cord then gave off: lower (T1), middle (T1) and upper (C5, C6, C7, C8, T1) branches and supply respective areas of the pectoralis minor muscle. The upper branch observed to receive branch from the lateral cord (**Figure 4**).

FIGURE 3: RIGHT BRACHIAL PLEXUS

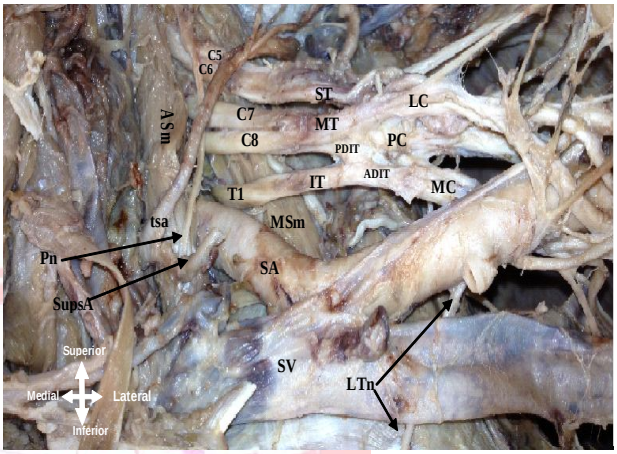

Figure 3: Photograph from 77 years old male cadaver showing the ventral view of the right brachial plexus. Note the Inferior trunk **(IT)** formed as the continuation of first thoracic nerve **(T1)**; the middle trunk **(MT)** formed by the union of eighth cervical nerve **(C8)** and seventh cervical nerve **(C7)**. The posterior cord receives the posterior division from the IT **(PDIT)**. (**MSm:** middle scalene muscle; **ASm:** anterior scalene muscle; **PDIT** and **ADIT**: posterior and anterior divisions of inferior trunk; **tsa:** transverse cervical artery).

FIGURE 4: RIGHT BRACHIAL PLEXUS

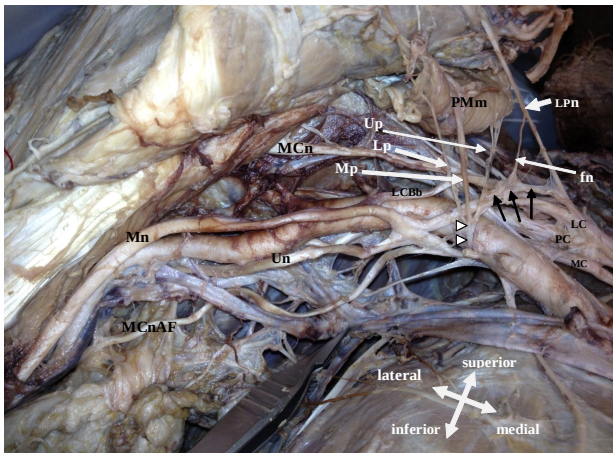

Figure 4: Photograph from 77 years old male cadaver showing the left brachial plexus. Note the Medial pectoral nerve (**white arrow heads**) originated from medial cord then arch below the axillary artery. It gave off Upper (**Up**); Middle (**Mp**) and Lower (**Lp**) branches supplying pectoralis minor muscle (**PMm**). The Upper branch joined with a branch from second branch of lateral cord (**black arrows**) before entering the **PMm**. Nerve filament (**fn**) from **LCBb** joined the **LPn.** (**See figure 1 for other definitions**).

The right lateral pectoral nerve (roots C5, C6, C7, and C8) noticed to arise from the lateral cord but received other nerve fibers from the second branch of the lateral cord (LCBb).

DISCUSSION

Variations involving the brachial plexus are not uncommon and have been linked with factors influencing the mechanism of limb muscles and peripheral nerves development during embryonic life [2]. These variations are clinically and surgically important.

In normal anatomy, the middle brachial plexus trunk is formed as a continuation of cervical nerve root C7 while the inferior trunk is formed following the union of roots C8 and T1. Variations on the trunks formation have been reported and involved mostly the union of the middle and superior trunks [10], length and caliber [9], and absence of superior trunk [1]. In our case, the middle trunk was formed following the union of ventral rami of cervical nerve roots C7 and C8, while the inferior trunk was solely formed by the ventral rami of first thoracic nerve root T1. This is a deviation from the common description of the brachial plexus.

Brachial plexus cords are formed by the union or continuation of the anterior and posterior divisions of the trunks. Usually, all trunks give out anterior and posterior divisions of which posterior divisions unite to form posterior cord. The anterior divisions from the superior and middle trunks join to form lateral cord while that from inferior trunk continues as medial cord [11, 13, 14]. In our case, the inferior trunk (root T1) did not give divisions instead it persist to form the medial cord (T1). This resulted into the posterior cord (roots C5 to C8) formed by the union of posterior divisions from superior and middle trunks without contribution from T1. All terminal nerves that originated from the posterior cord lack fibers from root T1.

Lateral pectoral nerve usually originates from the lateral cord or following union of branches from anterior divisions of superior and middle trunks with roots C5,C6 and C7 [2, 11], however, in the present case, the left lateral pectoral nerve originated from roots C5, C6,C7 and C8. Whilst the right lateral pectoral nerve originated from the lateral cord but received another nerve filament from second branch of the lateral cord (LCBb).

Medial pectoral nerves usually originate from the medial cord roots C8 and T1 [11, 13, 14] or anterior division of middle trunk or lower trunk roots C7 and C8 [2], however, the present case showed variations on both right and left sides. Left medial pectoral nerve originated from the lateral cord with roots C5, C6, C7 and C8. The right medial pectoral nerve originates from medial cord, and then gave off three branches. Lower and middle branches originated solely from root T1, while upper branch joined with branch from lateral cord hence has nerve fibres from root C5, C6, C7, C8 and T1. These are novel findings and to our knowledge have never been reported. These variations on pectoral nerves are clinically important to surgeries for example mastectomy and orthopaedic procedures.

Median nerve is formed by the fusion of three branches; two from the lateral cord, and one from the medial cord. This phenomenon correlates with previous report by Sargon *et al.,* [12], and its irregular oblique and close course of the unusual two nerve branches with the axillary artery may compress the vessel hence affect the blood supply to the upper limb.

Medial cutaneous nerve of the arm and forearm usually are formed by roots C8 and T1 [14] in the current case they were formed solely by root T1.

Ulna nerve is usually formed by roots C8 and T1, but often receives fibres from C7 [14]. In the present case it was formed by nerve roots C5, C6, C7, C8 and T1. This variation is important to the clinical or surgical practices involving the sensory tool of the upper limb (hand).

EMBRYOLOGICAL NOTE AND CONCLUSION

Variations in the formation and branching pattern of brachial plexus can be explained through neuronal growth cones behaviours during embryonic development which are mediated by intracellular signalling pathways that link guidance receptors regulated by expression of chemoattractants and chemorepulsants, to the cytoskeleton [5]. Alterations in signalling between mesenchymal cells and neuronal growth cones can lead to significant variations of which once formed

would persist postnatally [4]. In the present case where the brachial plexus showed multiple variations might be a result from bilateral alterations in mesenchymal cells and growth cones signalling. Understanding of these anatomical variations of the brachial plexus is important and might benefit the physicians, surgeons, anaesthesiologist and neuroanatomists during their routine procedures involving the cervical, axillary and the upper limb regions.

LIST OF ABBREVIATIONS

i. **C5-C8-**Firth to eighth cervical spinal nerves
ii. **T1-**First thoracic spinal nerve
iii. **LCBa-** First branch from brachial plexus lateral cord
iv. **LCBb-**Second branch from brachial plexus lateral cord
v. **Nn-**Common nerve trunk formed by union of nerve branch from medial cord and LCBa
vi. **Nb-**Nerve branch from common nerve trunk

COMPETING INTEREST

The authors declare that they have no competing interests.

ACKNOWLEDGEMENT

Author expressing thanks to Prof. Yoh-ichi Satoh and Dr. Yan Jun for their moral and material support and all members in the Department of Anatomy, Iwate Medical University for their encouragement.

REFERENCES

1. Adam AH, Mohammed AM, Grebballa A, Riziq S. Absence of upper trunk of the brachial plexus. Int J Appl Basic Med Res. 2011; 1(2): 123-124.

2. Anjali Aggarwal K, Harjeet K, Sahni Daisy, Aditya Aggarwal. Bilateral multiple complex variations in the formation and branching pattern of brachial plexus. Surg Radiol Anat. 2009; 31: 723-731.

3. Bannister LH, Berry MM, Couins P, Dyson M. Gray's anatomy - The anatomical basis of medicine and surgery. 38th Ed. Edinburgh London: Churchill Livingstone. 2000. p.1267.

4. Brown MC, Hopkins WG, Keyness RJ. Axon guidance and target recognition. In: Essentials of Neuro Deveolpment. Cambridge University Press. 1991. p 46-66.

5. Dent EW, Tang F, Kalil K. Axon guidance by growth cones and branches: Common cytoskeletal and signaling mechanisms. Neuroscientist. 2003; 9(5): 343-353.

6. Havaldar PP, Gupta A, Rajasekhar HV. Case report: Variation in the formation of brachial plexus and its relation with axillary artery. Current Neurobiology. 2012; 3(1):7-9.

7. Johnson EO, Vekris M, Demesticha T, Soucacos PN. Neuroanatomy of the brachial plexus: normal and variant anatomy of its formation. Surg Radiol Anat. 2010; 32(3):291-7.

8. Kocabiyik N, Yalcin B, Kilic C, Ozan H. Multiple anomalies of the brachial plexus: a case report. Neuroanatomy. 2007; 6: 21–23.

9. Leinberry CF, Wehbé MA. Brachial plexus anatomy. *Hand Clin*. 2004; 20(1):1-5.

10. Matejcik V. Aberrant formation and clinical picture of brachial plexus from the point of view of a neurosurgeon. *Bratisl Lek Listy*, 2003; 104(10):291–299.

11. Moore KL, Anne MR Agur, Dalley AF. Essential Clinical Anatomy. 4th Ed. Lippincott, Williams & Wilkins. 2010; p. 438.

12. Sargon MF, Uslu SS, Celik HH, Akºit D. A variation of the median nerve at the level of brachial plexus. *Bull Assoc Anat* (Nancy). 1995; 79(246):25-26.

13. Snell RS. Clinical anatomy by regions. 8th Ed. Lippincott Williams&Wilkins. 2006. p 446-448.

14. Standring S. Gray's Anatomy: The anatomical basis of clinical practice. 40th Ed. Churchil Livingstone, Elservier. 2008. p 819- 823.

How to cite this article:

Gabriel J Mchonde, Flora M Fabian, Hortensia G Nondoli. Bilateral multiple variations in the formation of the brachial plexus and its terminal nerves. A case report. Int J Anat Res, 2013;02:78-82.