

MORPHOMETRY AND VARIATIONS OF MALLEUS WITH CLINICAL CORRELATIONS

Vinayachandra P H ¹, Viveka S ^{*2}, Sudha M J ³, Balakrishna Shetty ⁴,
Santhosh Kuriakose ⁵, Srinivasa Sagar ⁶.

¹ Associate Professor, Dept. of Anatomy, Kannur Medical College, Anjarakandy, India.

^{*2} Assistant Professor, Dept. of Anatomy, Azeezia Institute of Medical Sciences, Kollam, India.

³ Assistant Professor, Dept. of Pharmacology, Azeezia Institute of Medical Sciences, Kollam, India.

⁴ Assistant Professor, Dept. of Anatomy, Azeezia Institute of Medical Sciences, Kollam, India.

⁵ Assistant Professor, Dept. of Anatomy, Amala Institute of Medical Sciences, Thrissur, India.

⁶ Post Graduate, Dept. of Anatomy, A J Institute of Medical Sciences, Mangalore, India.

ABSTRACT

Background: Ossicular morphology and morphometric considerations play cornerstone importance in reconstructive surgeries. An attempt is made to have an insight into such morphological variations and evaluate the morphometric values of malleus in south Indian population through cadaveric dissection.

Materials and methods: 25 human head specimens taken from the dissection hall, after removal of brain and duramater, subarcuate fossa and arcuate eminence of the petrous part of the temporal bone were chipped off with help of fine edged chissel and hammer. With help of bone cutter the tegmen tympani forming the remaining roof was removed, till the middle ear cavity and three ossicles are properly exposed and identified.

Results: Malleus height ranged from 6.94 mm to 7.78 mm on both sides with average of 7.37mm on right and 7.51 mm on left. Weight ranged from 16.85 mg to 19.25 mg with average of 18 mg on right side and 18.52 mg on left both side. Length and weight of left malleus bones were statistically more than their right counterparts.

Conclusions: Morphologically malleus showed lesser variations in comparison to stapes. The left sided malleus dominated the right sided ones in both length and weight.

KEYWORDS: Malleus; Morphometry; Morphological variations; Cadaveric dissection; Manubrium.

Address for Correspondence: Dr. Viveka S. MD (Anatomy), DNB (Anatomy), Assistant Professor, Department of Anatomy, Azeezia Institute of Medical Sciences, Kollam, India.

E-Mail: vivekabharathi@gmail.com

Access this Article online

Quick Response code



Web site: International Journal of Anatomy and Research
ISSN 2321-4287
www.ijmhr.org/ijar.htm

Received: 24 Dec 2013

Peer Review: 24 Dec 2013 Published (O):31 Jan 2014

Accepted: 09 Jan 2014 Published (P):30 Mar 2014

INTRODUCTION

The middle ear bones in mammals are derived from bones in the dentary bone (mandible) of Therapsids. The tympanic, malleus, and incus are homologous to the angular, articular, and quadrate bones. In early Therapsids, the quadrate, angular and articular were directly connected to the dentary bone in the jaw hinge. These bones were essential for jaw movement [1]. The malleus is the largest of the ossicles. The word malleus is derived from latin word, *malleus* meaning hammer. Its shape resembles a mallet.

Malleus has a head, neck, handle (manubrium) and anterior and lateral processes. Situated in the epitympanic recess, the head is the upper end of malleus, articulates with incus through incudomalleolar joint. The articular facet has two parts, upper and lower, inclined at right angles to each other. Narrow neck situated below the head and proceeds inferiorly as handle of malleus. Handle of malleus, directed posteromedially is connected to tympanic membrane by its lateral margin. It diminishes in its size towards its free end. Near the upper end

of handle of malleus, the tendon of tensor tympani is attached. Just below the neck, there is an anterior projection, referred as anterior process, connected to the petrotympanic fissure. From the root of handle of malleus, conical lateral process arise and is attached through anterior and posterior malleolar folds to upper part of tympanic membrane.

The cartilaginous precursor of the malleus originates as part of the dorsal end of Meckel's cartilage. With the exception of its anterior process, the malleus ossifies from a single endochondral center which appears near the future neck of the bone in the fourth month in utero. The anterior process ossifies separately in dense connective tissue and joins the rest of the bone at about the sixth month of fetal life [2].

Studies concentrating on the morphometry of ossicles are sparse from Indian subcontinent. Knowledge of ossicular morphology dates back to fifteenth century [3]. Morphological variations have been reported in the past in all the three ossicles [4,5]. Schafer and Symington have studied all three ossicles and they report the length of malleus to be 8 to 9 mm [6]. Anson and Bast studied 22 sets of ossicles and concludes that the morphological variations in malleus and incus are less frequent than stapes [7]. They report that the length of malleus varies between 7.61 – 9.11 mm.

In the present study aim was to study the morphometry and morphometric variation, if any, in the malleus of small sample of cadavers of south Indians.

MATERIALS AND METHODS

Twenty five human head specimens taken from the dissection hall of A J Institute of Medical Sciences, Mangalore were used for the study. The cranial cavity and its middle cranial fossa were properly exposed after removal of brain and duramater. Portion above the internal acoustic meatus, Sub arcuate fossa and arcuate eminence of the petrous part of the temporal bone were chipped off with help of fine edged chisel and hammer. Care was taken so that chipped off portion from exceeding 1 cm from the surface of the middle cranial fossa. With help of bone cutter the tegmen tympani forming the

remaining roof was removed, till the middle ear cavity and three ossicles are properly exposed and identified.

With help of magnifying lens - observations were made in exposed part. Malleus identified easily by its globular head and incus by its body. Following the body and long process of the lower end of incus the head of the stapes was reached and gently pulled with help of a pointed forceps. Stapes foot plate was separated from the oval window and stapes in toto delivered out of the middle ear cavity.

By using ECG recording paper, having a scale of 1mm, the length and width of the malleus was noted. Using electronic weighing machine – the weights of the stapes bone thus extracted noted after it was completely dried. The measurements were tabulated for evaluation, comparison and interpretation. Morphological variations – if any were noted. Variations of the individual malleus bones noted.

RESULTS

Metric Considerations:

Malleus height ranged from 6.94 mm to 7.78 mm on both sides with average of 7.37mm on right and 7.51 mm on left (graph 1). Weight ranged from 16.85 mg to 19.25 mg with average of 18 mg on right side and 18.52 mg on left both side (graph 2). Table 1 shows compilation of values of both right and left malleus. Length and weight of left malleus bones were statistically more than their right counterparts.

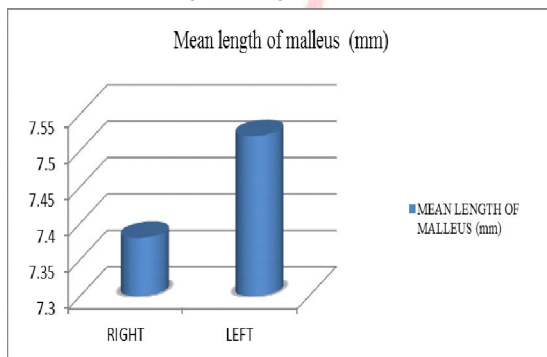
Table 1: Tabulation of parameters of malleus of both sides. n = number of malleus, students t test value and pearsons value derived from comparison of right and left malleus.

Parameters Malleus	Length (in mm)	Weight (in mg)
Mean	7.45	18.26
Standard deviation	0.39	0.78
Maximum	7.78	19.25
Minimum	6.94	16.85
N	50	50
T	0.291	0.957
Pearsons	0	0.37

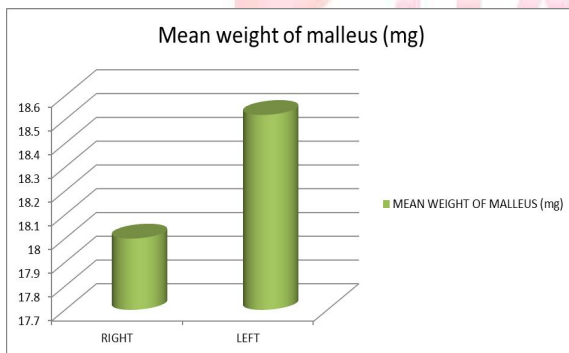
Morphological Considerations:

Malleus showed minimum variations in comparison to other ossicles. Variations ranged from large globular head to small head. Nodular bony projection from the head was noted in one of the right sided malleus. One left sided malleus showed thin and short handle. Rudimentary anterior and lateral process was encountered in another left sided malleus.

Graph 1: Mean length of right and left malleus in mm.



Graph 2: Mean weight of right and left malleus in mg.



DISCUSSION

Anatomy of the ossicles of tympanic cavity has unfortunately remained as an area of peripheral interest. Scant data exists on individual features and variations in each bone. The multiplicity of the contributing developmental sources only serves to add to the range and frequency of the variations in the stapes. This is well evidenced by the amount of variations noted in this study of 25 sets of the stapes. Not surprisingly, the bones and their anomalies are definitive components of many congenital head and neck defects such as Treacher- Collins syndrome and Pierre Robin syndrome. In many such syndromes of first and second arch involvement, obvious auditory defects have been identified in newborns.

Our study results correlates with previous studies. Bouchet has reported the length of

malleus to be 7.9 mm [8]. Masali et al [9], Arrensburg et al [4], Harada et al [10] and Aycan et al [11] have reported the morphological features of malleus and reported lengths of malleus are 7.6 mm, 7.3 mm, 8 mm and 8.1 mm respectively. In the present study the length of malleus was found to be 7.45 mm. Ramirez has studied 23 sets of malleus and reported 8.18 mm length [12].

The study from Indian subcontinent though had done on malleus morphometry; westerners have done the study using more morphometric parameters. The parameters of the malleus studied include total length (maximal distance between the top of the head and the end of the handle), length of handle (distance from the end of the lateral process to the end of handle) and length of head and neck (maximal distance between the top of the head and the end of the lateral process). Vincentiis & Cimino studied malleus from infants, juvenile, adult male & females. They have reported a difference between right and left malleus. In our study there was no significant difference noted between male and female malleus. This is in accordance with many previous studies [13,14]. Our study goes in contrast with another study from Indian subcontinent in which 60 malleus showed skewed morphology of males and females malleus [15]. The morphometric analysis of malleus may help in understanding various middle ear pathologies. It may aid the otorhinolaryngologists in ossicular replacement surgeries.

CONCLUSION

Morphologically malleus showed lesser variations in comparison to stapes. The left sided malleus dominated the right sided ones in both length and weight.

Conflicts of Interests: None

REFERENCES

- [1]. Allin EF. Evolution of the mammalian middle ear. J Morphol. 1975 Dec;147(4):403-37.
- [2]. Standring, Susan. Gray's Anatomy, Anatomical basis of clinical practice. 40th ed: Elsevier, 2009.
- [3]. Arensburg B, Harell M, Nathan H. The human middle ear ossicles, morphometry and taxonomic implications. J Hum Evol. 1981;10:199-205.
- [4]. Arensburg B, Nathan H. Observations on a notch in the short (Superior or posterior) process of the incus. Acta Anat 1971;78:84-90.

- [5]. Sarrat R, Guzman G, Tores A. Morphological variations of Human ossicula tmpani. *Acta Anat* 1988;131:146-149.
- [6]. Schafer EA, Symington J, Bryce TH. *The Ear. Quain's Elements of Anatomy*. 11th ed, Longmans Green and Co, 1999, p.286-289
- [7]. Bast TH, Anson BJ. *The temporal bone and the ear*. 3rd ed Springfield, 1949, p.337-377
- [8]. Bouchet A, Giraud M. Contribution a l'etude morphologique et radiologique des osselets de l'ouïe. *Compte rendu de l' Association des Anatomists 53 Congrès*, 1968; 141:588-600.
- [9]. Masali M. The ear bones and the vertebral column as indications of taxonomic and column as indications of taxonomic and with reference to the origin of man. Rosenberg and Sellier, Torino, 1968.
- [10]. Harada, O. & Ishii, H. The Condition of the auditory ossicles in microtia. *Plast. Reconst. Surg.* 1972;50:48-53.
- [11]. Aycan, K. and Unur, E. & Bozkir, M.G. Anatomical study of malleus. *J. Health Sciences.*, 1990;1:152-58.
- [12]. E, Ramirez L M and Ballesteros L. Anthropometry of the Malleus in Humans: A Direct Anatomic Study. *Int. J. Morphol.* 2013;31(1):177-183.
- [13]. Urbantschitsch V, Zur Anatomie der Gehörknöchelchen des Menschen. *Archiv Fur Ohrenheilkundv* 1976;11:1-3.
- [14]. Siori MS, Monchietto MJ, Masali M, Morphometrics of human auditory ossicles from Antinoe Necropolis (Egypt). *Int J Anthropol* 1995;10:29-36.
- [15]. Singh K, Chhabra S, Sirohiwal BL, Yadav SPS, Morphometry of Malleus a Possible Tool in Sex Determination. *J Forensic Res.* 2012;3:152.

How to cite this article:

Vinayachandra P H, Viveka S, Sudha M J, Balakrishna Shetty, Santhosh Kuriakose, Srinivasa Sagar. MORPHOMETRY AND VARIATIONS OF MALLEUS WITH CLINICAL CORRELATIONS. *Int J Anat Res* 2014;2(1):191-94.