

Case Report

ELONGATED STYLOID PROCESS: A REPORT OF TWO CADAVERIC CASES

Komala Nanjundaiah *¹, Radhika. P.M ², Veena Vidya Shankar ³, Prathap K J ⁴.

*¹ Associate Professor, ² Assistant Professor, ³ Associate Professor, ⁴ Assistant Professor.

Department of Anatomy, M.S.Ramaiah Medical College, Bangalore. Karnataka, India.

ABSTRACT

Introduction: Styloid process is a part of temporal bone. It measures 2 to 3 cms in length and lies antero-medial to the mastoid process. An elongated styloid process can compress the vital vessels and nerves close to it. This can lead to pain, foreign body sensation in the pharyngeal region and can also cause dysphagia.

Observation: During routine dissection, we encountered elongated styloid process in two cadavers. In one it was unilateral and in another it was bilateral. The measurements of the elongated styloid process were taken using digital Vernier slide calipers.

Conclusion: The awareness of the embryological cause and the clinical implications of an elongated styloid process are important for accurate diagnosis and treatment

KEYWORDS: Elongated styloid process, Compression, Dysphagia, Cervical pain, Eagle's syndrome.

Address for Correspondence: Dr Komala N, Associate Professor, Department of Anatomy, M.S.Ramaiah Medical College, M.S.R.I.T Post, Bangalore, Karnataka, India - 560054.

Phone: 9480259177, 080-23421593. **E-Mail:** komas2001@yahoo.com

Access this Article online

Quick Response code



Web site: International Journal of Anatomy and Research
ISSN 2321-4287
www.ijmhr.org/ijar.htm

Received: 04 June 2014

Peer Review: 04 June 2014 Published (O):30 June 2014

Accepted: 18 June 2014 Published (P):30 June 2014

INTRODUCTION

Styloid process of temporal bone is a slender projection measuring 2 to 3 cms in length which lies antero-medial to the mastoid process. The tip of the styloid process is of surgical importance because vital structures such as external carotid artery, internal jugular vein, facial nerve, glossopharyngeal nerve, the accessory and vagus nerves are in medial relation with the styloid process. The structures attached to it are stylopharyngeus, stylohyoid, styloglossus muscles; stylohyoid and stylomandibular ligaments. The process is covered by the parotid gland laterally [1]. The elongated styloid process can be accompanied by calcification of the stylohyoid and stylomandibular ligaments. This can lead to symptoms such as dysphagia, odynophagia, facial pain, ear pain, headache,

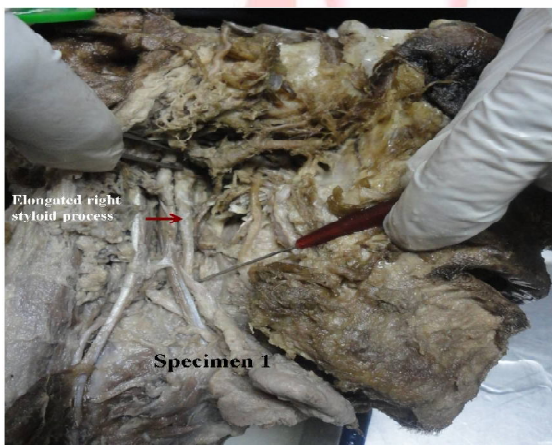
tinnitus and trismus. This set of symptoms associated with the elongated styloid process is called Eagle's syndrome. The clinical features of the elongated styloid process were first described by Eagle. Later he described the two distinct syndromes associated with anomalous growth of the styloid process: the styloid process syndrome and the carotid artery syndrome[2,3,4].

The present cases reported were found incidentally during the routine dissection teaching for first MBBS students. The knowledge of elongated styloid process is of immense importance to clinicians, radiologists and ENT Surgeons. In this report, the incidence, embryological basis and clinical importance of elongated styloid process are discussed.

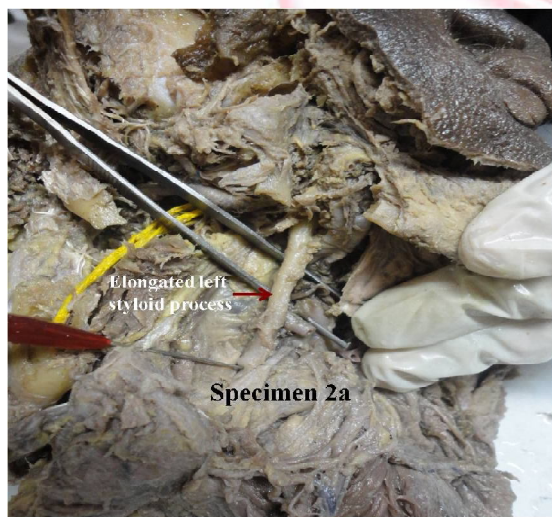OBSERVATIONS

During routine dissection, we encountered elongated styloid process in two cadavers aged around 55 – 60 years. One was a male cadaver (Specimen 1) in which the elongation was found on the right side. The styloid process on the left side was normal. In another cadaver which was a female, (Specimen 2a, 2b) the elongated styloid process was seen bilaterally. The length and thickness of the elongated styloid processes were measured using a digital Vernier slide calipers and the same were tabulated.(Table -1)

Specimen 1: unilateral elongated styloid process on the right side. The probe is at the tip of the styloid process.



Specimen 2a, 2b: Bilateral elongated styloid process.. The probe is at the tip of the styloid process.



DISCUSSION

The length of styloid process in various studies ranged from 0.7 cm to 4 cm. [5,6,7,8,9] Jung et al suggested that the styloid process is elongated, when its length exceeds 45 mm[10]. Keur et al stated that, if the length of the process or the mineralised part of ligaments as seen in radiographs was 30 mm or more can be called an elongated styloid process[11].

In a study of 2000 cases, there were only 11 cases (0.55%) of styloid process having length of more than 4 cm[12]. Harma gives an incidence of 4-7% of elongated styloid process[13].

Reichert’s cartilage of second branchial arch gives rise to the styloid process, stylohyoid ligament, the lesser cornu and upper half of body of the hyoid bone. Embryologically, the stylohyoid chain extends between the temporal bone and the hyoid bone. It can be divided into tympanohyal, stylohyal, ceratohyal, hypophyal parts. Tympanohyal and stylohyal parts form the stylohyoid process. Ceratohyal- forms the stylohyoid ligament and Hypophyal forms the lesser cornu horn of the hyoid bone[14].

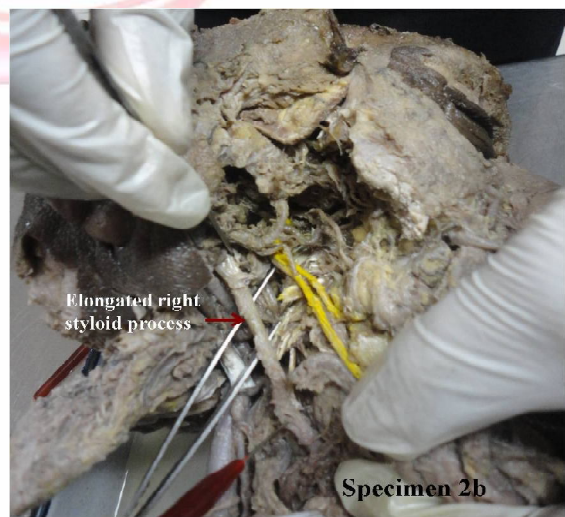


Table 1: Measurements of the elongated styloid process.

Specimen	Side	Length	Thickness at		
			Base	Midway between base and tip	Tip
Specimen 1 (Male)	Right side	45.28mm	4.08mm	4.05mm	1.78mm
Specimen 2a (Female)	Left side	58mm	6.44mm	3.99mm	2.84mm
Specimen 2b (Female)	Right side	61.37mm	5.38mm	4.22 mm	2.37 mm

Elongation of styloid process can be congenital in origin. The mechanical stresses which occur during the fetal development causes stretching of the second branchial arch (Reichert’s cartilage) which leads to the elongation[15].

Styloid ligament has a potential for ossification. Varying degrees of ossification of the stylohyoid cartilage causes elongation of styloid process.

Trauma can cause ossification at the end of the styloid process down the length of the stylohyoid ligament. An abnormal healing after the trauma can also initiate the calcification process. Even in the absence of recognisable trauma, ossification and elongation of the styloid process can exist as an anatomical variant [16].

The increase in the length of the styloid process has clinical significance. Thot et al stressed that elongation of styloid process alone may not be a risk factor, but deviation of the elongated process anteriorly and medially causes the symptoms of Eagle's syndrome [6]. Most of the patients have classical symptoms of Eagle's syndrome but some patients may have localized pain or pain radiating to jaw and ear which simulates pain of dental origin [15]. The neurological symptoms seen in Eagle's syndrome can be due to the approximation of the glossopharyngeal nerve with the stylohyoid ligament [17]. Elongated styloid process can also cause transient ischaemic attack due to compression of internal carotid artery [18]. It has been reported that elongated styloid process can also cause difficulty during intubation [19].

If digital palpation of the styloid process in the tonsillar fossae increase the pain and injection of an anaesthetic agent into the tonsillar fossae provides relief of pain, it is suggestive of Eagle's syndrome. The treatment for Eagle's syndrome is surgical removal of the calcified styloid process [20].

CONCLUSION

The awareness of the incidence of the elongated styloid process is essential for a surgeon, to evaluate a patient with history of cervical pain. The knowledge of the embryology of the styloid apparatus and the structures related to it helps in proper diagnosis and treatment of Eagle's syndrome. In addition to clinical diagnosis the presence of elongated styloid process can also be confirmed by radiographs.

Conflicts of Interests: None

REFERENCES

- [1]. Williams PL. Gray's Anatomy. 38th Ed., London, ELBS with Churchill Livingstone. 1999; 592.
- [2]. Eagle W W. Elongated styloid process: further observations and a new syndrome. Arch Otolaryngol 1948; 47:630-40.
- [3]. Baddour HM, McAnear JT, Tilson HB. Eagle's syndrome. Report of a case. Oral Surg Oral Med Oral Pathol 1978;46:486-494.
- [4]. Winkler S, Sammartino FJ Sr, Sammartino FJ Jr, Monari JH. Stylohyoid syndrome. Report of a case. Oral Surg Oral Med Oral Pathol 1981; 51(2):215-217.
- [5]. Kaufman SM, Elzay RP, Irish EF. Styloid process variation. Radiologic and clinical study. Arch Otolaryngol 1970; 91:460-463.
- [6]. Thot B, Revel S, Mohandas R, Rao AV, Kumar A. Eagle's syndrome. Anatomy of the styloid process. Indian J Dent Res 2000; 11(2):65-70.
- [7]. Chandler JR. Anatomical variations of the stylohyoid complex and their clinical significance. The Laryngoscope 1977; 87(10):1692-1701.
- [8]. Ferrario VF, Sigurta D, Daddona A, Dalloca L, Miani A, Tafuro F, Sforza C. Calcification of the stylohyoid ligament: incidence and morphoquantitative evaluations. Oral Surg Oral Med Oral Pathol 1990; 69:524-9.
- [9]. Zaki H S, Greco C M, Rudy T E, Kubinski J A. Elongated styloid process in a temporomandibular disorder sample: prevalence and treatment outcome. J Prosthet Dent 1996;75(4):399-405.
- [10]. Jung T, Tschenitschek H, Hippen H, Schneider, Borchers L. Elongated styloid process: when is it really elongated?. Dentomaxillofacial Radiol 2004; 33:119-24.
- [11]. Keur JJ, Campbell JP, McCarthy JF, Ralph WJ. The clinical significance of the elongated styloid process. Oral Surg Oral Med Oral Pathol 1986;61(4):399-404.
- [12]. Massey EW, Wayne, Bethesda. Facial pain from an elongated styloid process. (Eagle's syndrome). South Med J. 1978; 71(9): 1156-1158.
- [13]. Harma R. Stylalgia: clinical experiences of 52 cases. Acta Otolaryngol. 1966; 224: 149.
- [14]. Magotra R, Razdan S. Elongated Styloid Process: Anatomical Variations. JK Science: Journal of Medical Education & Research. 2008; 20: 203-5.
- [15]. Das S, Suhaimi FH, Othman F, Latiff AA. Anomalous styloid process and its clinical implications. Bratisl Lek Listy. 2008; 109(1):31-33.
- [16]. Steinmann EP. Styloid syndrome in absence of an elongated process. Acta Otolaryngol 1968; 66:347-56.
- [17]. Soh K B. The glossopharyngeal nerve, glossopharyngeal neuralgia and the Eagle's syndrome — current concepts and management. Singapore Med J 1999; 40(10):659-65.
- [18]. Chuang WC, Short JH, McKinney AM, Anker L, Knoll B, McKinney ZJ. Reversible left hemispheric ischemia secondary to carotid compression in Eagle syndrome: surgical and CT angiographic correlation. AJNR Am J Neuroradiol. 2007; 28(1):143-45.
- [19]. Kawai T, Shimozato K, Ochiai S. Elongated styloid process as a cause of difficult intubation. J Oral Maxillofac Surg. 1990;48(11):1225-8.
- [20]. Eagle WW. The symptoms, diagnosis and treatment of the elongated styloid process. Am Surg. 1962; 28:1-5.

How to cite this article: Komala Nanjundaiah, Radhika. P.M, Veena Vidya Shankar, Prathap K J. ELONGATED STYLOID PROCESS: A REPORT OF TWO CADAVERIC CASES. Int J Anat Res 2014;2(2):431-433.