

## Case Report

# LANGER'S AXILLARY ARCH AND ITS CLINICAL IMPLICATIONS

Jyothi K C <sup>\*1</sup>, Anupama K <sup>2</sup>, Shailaja Shetty <sup>3</sup>, Radhika P M <sup>4</sup>.

<sup>\*1,2,4</sup> Assistant Professor, <sup>3</sup> Professor & Head.

Department of anatomy, M S Ramaiah Medical College, Bangalore, India.

## ABSTRACT

**Introduction:** The axillary arch muscle of Langer is the most common anatomical variant of axillary musculature which is of clinical and surgical importance. It may lead to neurovascular compression syndrome in the cervico-axillary region and can be misinterpreted while examining axilla and also impairs movements of shoulder joint.

**Observation:** During routine dissection of axilla for undergraduate teaching, an unusual muscular slip in the left axilla was observed. The muscular slip was extending from latissimus dorsi muscle to undersurface of pectoralis major muscle, arching over axillary vessels and cords of brachial plexus.

**Conclusion:** The axillary arch may cause obstruction to axillary vessels and nerves and may be involved in thoracic outlet syndrome and shoulder instability. The knowledge of this muscular variant could help to minimize intraoperative complications related to surgeries in or nearby axilla such as mastectomy, breast reconstruction and axillary lymphadenectomy or lymph node biopsy.

**KEYWORDS:** Axillary arch, Langer's muscle, Axilla, Anomalous muscle.

**Address for Correspondence:** Dr Jyothi K C, Assistant Professor, Department of Anatomy, M. S. Ramaiah Medical College, MSRIT Post, Bangalore. 560054, India. Mobile: +919731346464.

**E-Mail:** jyothimohankc@gmail.com

## Access this Article online

### Quick Response code



**Web site:** International Journal of Anatomy and Research  
ISSN 2321-4287  
[www.ijmhr.org/ijar.htm](http://www.ijmhr.org/ijar.htm)

Received: 27 June 2014

Peer Review: 27 June 2014 Published (O):31 July 2014

Accepted: 14 July 2014 Published (P):30 Sep 2014

## INTRODUCTION

Human beings are individualistic creature and this is reflected in the human anatomy which is subjected to a large number of anatomical variations. The axilla is a pyramidal area between the upper thoracic wall and the arm. It contains axillary vessels, cords and branches of brachial plexus, lymph nodes, and loose areolar tissue with fat and axillary tail of breast in many instances[1].

A number of accessory muscle slips may arise from Pectoralis muscle or may be present in axillary region have been described under different names. These abnormal muscle slip may arise from lateral border of pectoralis major muscles, from ribs and costal cartilages or from latissimus dorsi muscle, midway in the posterior

axillary fold crossing over the axillary vessels and nerves and have variable insertions [1,2].

The various terminologies used to describe this variant structure are, axillary arch, axillopectoral muscle, Achselbogen, Langers axillary arch, muscular axillary arch, arcus axillaris, pectoral dorsalis muscle [3].

It is stated that axillary arch muscles were first discovered by Ramsay in 1795 and Langer in 1846 was credited for the first description of this clinically troublesome variation [4].

The incidence has been reported to be varying with different authors. According to an Indian author Pai MM's study it is 1.47% and also quoted its incidence as 7% in Japanese, 10% in Belgian, 0.25% in British population [5].

It is more commonly seen among Chinese than in Caucasian population. It is more common in females than in males and is seen as bilateral variation than unilateral [6].

Testut referred to it as the axillary arch of Langer in 1884 and classified these anomalous bands in to complete and incomplete types. The complete type stretches from the axillary portion of latissimus dorsi to the posterior layer of the pectoralis major tendon at its insertion on the humerus. The incomplete type extends from latissimus dorsi and does not insert in to pectoralis major tendon, but on the axillary fascia, biceps brachii muscle, coracobrachialis muscle or to the coracoids process [7].

The nerve supply of the axillary arch has been reported different in various literatures. It has been reported that it receives nerve supply from thoracodorsal nerve, medial pectoral nerve, intercostobrachial nerve [7,8,9].

It is widely accepted that axillary arch muscle is a remnant of the panniculus carnosus, and is an example of the atavistic type of muscle. Many of these are well developed and better represented in apes than in humans [2, 10].

The present paper reports a case of complete type of axillary arch and its clinical implications.

### CASE REPORT

During routine dissection teaching of axillary region for undergraduate students in Anatomy Department, M S Ramaiah Medical College, Bangalore, we found an anomalous muscle slip in the left axilla.

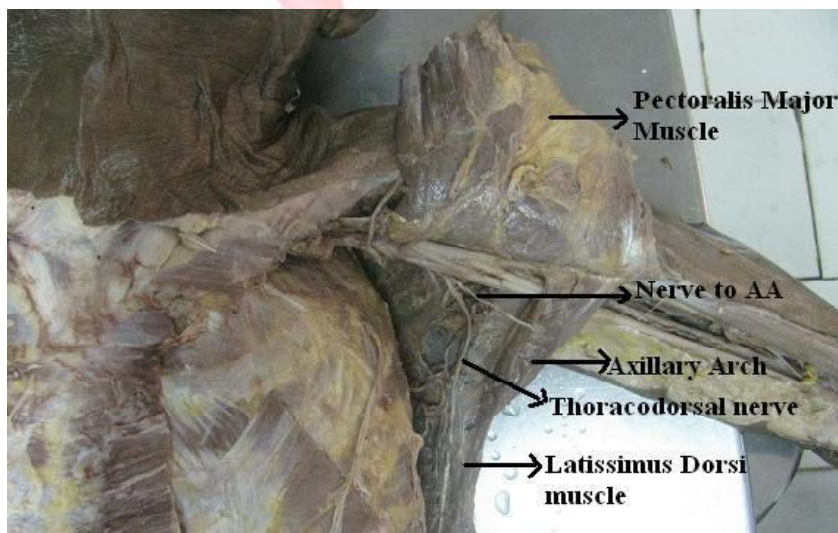
The muscle was fleshy throughout its length, extending from latissimus dorsi muscle to undersurface of pectoralis major muscle. It measured a length of 8.5 cm, maximum width of 3.8 cm at Pectoral end and 1.5 cm at latissimus dorsi. It was passing superficial to third part of axillary vessels and cords and branches of brachial plexus. It was receiving nerve supply from a branch arising from posterior cord near the origin of thoracodorsal nerve. (Fig. 1)

### DISCUSSION

Smith AR reported a case of bilateral incomplete type of anomalous musculotendinous bands in consistent with axillary arch of Langer in an 81 year old male cadaver dissected to teach physical therapy students. This band was said to tauten and compress the underlying neurovascular structures during passive abduction and external rotation of shoulder [11].

Merido-Velasco et al reported four axillary arches in 3 out of 32 adult human dissected cadavers. In first cadaver bilateral and complete type was found and both were innervated by thoracodorsal nerve and crossed the axillary neurovascular bundle anteriorly. The unilateral and incomplete type in second cadaver also innervated by thoracodorsal nerve, crossed anterior to the axillary neurovascular bundle and attached to the coracobrachialis muscle. In third cadaver it was unilateral and incomplete type innervated by medial pectoral nerve and crossed posterior to the axillary neurovascular bundle and attached to the coracoids process.

**Fig. 1:** Left Axilla showing Axillary contents and presence of Langer's Axillary Arch.



In first two cadavers there was possibility of compression of the neurovascular structures passing deep to the muscle band and can also contribute to hyperabduction syndrome [7].

The clinicians should examine for the presence of an axillary arch in patients with signs and symptoms of cervico-axillary compression causing thoracic outlet and hyper-abduction syndromes [7,12].

Langer's arch can be occasionally palpable as an axillary mass during clinical examination and can be confused with enlarged lymph nodes or soft tissue tumours [12].

In another study by Bertone VH et al, they found 9 axillary arches in 78 dissected axillae and stated that the knowledge of such a muscle variation and the possibility of finding it during surgical procedures is essential for lymph node staging and lymphadenectomy and also is important in differentially diagnosing the compression of axillary vessels and brachial plexus [9].

Hafner et al and Sachatello presented a similar case in 17 years old and 15 years old female patients respectively who came with the complaints of intermittent swelling, pain and bluish discoloration of arm with fullness of the affected axilla and loss of normal concavity. Surgical exploration in both the cases revealed the presence of an aberrant muscle bundle. The symptoms resolved completely after surgical resection of the muscle. Hence any patients coming with the above signs and symptoms should be examined for the presence of axillary arch as excision of it is curative [13, 14].

The first extensive review of shoulder MRI data to analyze the axillary arch muscle and its anatomic relations to lymph nodes and the brachial plexus was carried out and concluded that MRI as the most suitable mode of identifying arch muscle in patient with upper limb pain and numbness [15].

Natsis et al reported the presence of the three commonly encountered anomalous muscle bands during axillary lymphadenectomy through extensive surgical and anatomical literature review as the Langer's axillary arch, the pectoralis quartus and the chondroepitrochlearis muscles and stated that the axillary arch may interfere in the approach of the axilla and cover

the lateral group of level I lymph nodes, so that they may not be completely cleared. Hence surgeons must be aware of the presence of these muscles within the surgical field of axillary lymphdenectomy [16].

## CONCLUSION

Unilateral complete type of axillary arch was found in 60 year old female cadaver. Anatomical variations of axilla are of great relevance due increasing surgical procedures done in this region for breast cancer, reconstructive procedures and axillary bypass operations. Fullness of axilla with loss of normal concavity and visible or palpable axillary mass may indicate the presence of axillary arch. It should be considered in patients with signs and symptoms of upper limb neurovascular compression similar to thoracic outlet syndrome and simple excision of the muscle is curative. Necessary preoperative knowledge for recognizing these muscles will avoid operative complications that may arise from them.

## AKNOWLEDGEMENT

I thank all the authors whose references have been quoted in this paper and my colleagues for their support and encouragement.

**Conflicts of Interests: None**

## REFERENCES

- [1]. Johnson D. Pectoral girdle, shoulder region and axilla. In: Gray's Anatomy. 40<sup>th</sup> edition. Standing S. Churchill Livingstone; Elsevier 2008: 811-814.
- [2]. Hollinshead WH. Anatomy for surgeons. Volume 3. 3<sup>rd</sup> ed. Philadelphia; Harper & Row 1958: 284-300.
- [3]. Vishnumukkala TR, Yalakurthi SR, Bharath NV, Kannan M. Int J Med Health Sci 2013; 2(2): 251-255.
- [4]. Bergman RA, Thompson SA, Afifi AK, Miyauchi R. Axillary Arch. In: Illustrated encyclopedia of Human anatomic variations: Opus I: Muscular System: anatomy atlases www.anatomyatlases.org.
- [5]. Pai MM, Rajanigandha, Prabhu L V, Shetty P Narayana K. Axillary arch (of Langer): incidence, innervations, importance. Online J Health Allied sci 2006; 5: 1-4.
- [6]. Rizk E, Harbaugh K. The muscular axillary arch: anatomy, embryological features and surgical implications. Surgeon 2005; 3(5): 325 -327.
- [7]. Merida-Velasco JR, Vazquez RJF, Velasco MJA, Perez SJ, Collado JJ. Axillary Arch: Potential cause of Neurovascular compression Syndrome. Clin Anat 2003; 16: 514 – 519.

- [8]. Ucerler H, Ikiz ZAA, Pinan Y. Clinical Importance of the Muscular Arch of the Axilla(Axillopectoral Muscle, Langer's Axillary Arch). Acta chir belg 2005; 105: 326-328.
- [9]. Bertone VH, Ottone NE, Tartaro ML, Quiros GD, Gonzalez DD, Bonardi PL et al. The morphology and clinical importance of the axillary arch.. Folia Morphol 2008; 67(4): 261-266.
- [10]. Kumar PJ, Padmalatha K, Prakash BS, Radhika PM, Ramesh BR. The Flexor Indicis Profundus- Its Morphology and clinical significance. JCDR 2013; 7(5): 933-935.
- [11]. Smith AR, Cummings JP. The axillary Arch: Anatomy and Suggested Clinical Manifestations. Journal of Orthopaedic & Sports Physical Therapy 2006; 36(6): 425-429.
- [12]. Orhan M, Kervancioglu P, Cocelli LP. The existence of axillary arch in human fetus and applied importance and clinical implications in axillary brachial plexus blocks. Int. J. Morphol 2012; 30(1): 272-278.
- [13]. Hafner F, Seinost G, Gary T, Tomka M, Szolar D, Brodmann M. Axillary vein compression by Langers axillary arch, an aberrant muscle bundle of the left Latissimus dorsi. Cardiovascular Pathology 2010; 19(3): 89-90.

**How to cite this article:**

Jyothi K C, Anupama K, Shailaja Shetty, Radhika P M. LANGER'S AXILLARY ARCH AND ITS CLINICAL IMPLICATIONS. Int J Anat Res 2014;2(3):481-84.