

## SYMPHYSIS PUBIS DIASTASIS

Senthilkumar Thiyagarajan

Professor, Head of the Department, Department of Musculoskeletal, The Oxford College of Physiotherapy, Bangalore, Karnataka, India. **E-Mail:** [senphysio1981@gmail.com](mailto:senphysio1981@gmail.com)

### Access this Article online

#### Quick Response code



DOI: 10.16965/ijpr.2016.142

#### International Journal of Physiotherapy and Research

ISSN 2321- 1822

[www.ijmhr.org/ijpr.html](http://www.ijmhr.org/ijpr.html)

Received: 02-06-2016

Accepted: 24-06-2016

Peer Review: 03-06-2016

Published (O): 11-08-2016

Revised: None

Published (P): 11-08-2016

### DESCRIPTION

A 24 years old women working in garment factory as export assistant at sarjapura, Bangalore. She fell down 6 months before from the stair steps with weight in the hand. Presently she has a complaint of pain on medial aspect of thigh, difficulty in walking, standing and climbing stairs. She consulted orthopedician at The Oxford Medical College, Attebele, Banglore. Orthopedician advised to go for pelvis X- ray. She was referred to our The Oxford, physiotherapy outpatient department on 27/5/2016. Physiotherapy examination and treatment was done with assistance of Ms. Gayathri, Third year physiotherapy student under my supervision. VAS scale shows pain level on 8. History of fall and mode of violence was revealed clearly. She was fine for past 6 months after fell down in the steps. But pain was started from one week before. Job nature was examined, she has to do frequent bending and twisting her back while doing her work. Pain was gradually started on the medial aspect right thigh and extending from groin area during walking and climbing stairs. Nature of pain was sharp and prickling pain on the groin area while walking. X-ray findings shows separation of symphysis pubis. Clinically termed as Symphysis pubis Diastasis. Physiotherapy management started with Ultrasound therapy on the pain full areas.

**KEY WORDS:** Symphysis Pubis Diastasis, Physiotherapy management, Ultrasound therapy, symphysis pubis.

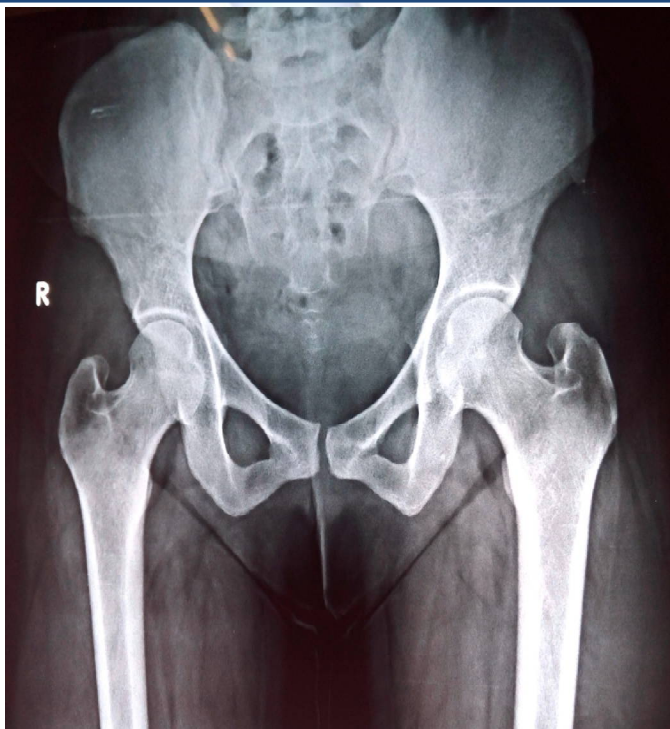


Figure showing the Symphysis Pubis Diastasis